

Bababeyli E.Yu., Bababeyli N.E.

Faculty of Medicine of Nakhchivan State University, Nakhchivan, Azerbaijan

EFFECTIVENESS OF OPTIMIZED DOSE OF OZONE SOLUTION IN MINIMALLY INVASIVE TREATMENT OF LIVER ABSCESES

e-mail: surgeon-scientist@mail.ru

The causes of liver abscesses include pathogenic bacteria, viruses, parasites (echinococcus), late, severe liver surgeries, relaparotomy, toxic products of industrial waste metabolism, trauma, toxic drugs, etc. The study examined the treatment outcomes of 140 patients who underwent minimally invasive surgical treatment for liver abscess between 2015 and 2025. Of these, 86 were women (61.4 %) and 54 were men (38.6 %). Liver abscesses were detected in the right lobe of 108 patients (77.1 %) and in the left lobe of 32 patients (22.9 %). With the minimally invasive methods we propose, catheterization is a more effective method. Continuous use of a drainage catheter is considered a safe and effective method. Since topical application and intravenous administration of an optimized dose of ozone solution for 5–7–10 days is a simple, easy, cost-effective, and efficient method, the percentage of patients recovered increased by 1.3–1.6 times, the incidence of complications decreased by 1.1–1.5 times, mortality decreased by 1.4–1.8 times, and the number of hospital days and financial costs were reduced.

Key words: liver abscess, minimally invasive surgery, optimized dose of ozone solution.

Бабабейлі Е.Ю., Бабабейлі Н.Е.

ЕФЕКТИВНІСТЬ ОПТИМІЗОВАНОЇ ДОЗИ РОЗЧИНУ ОЗОНУ ПІД ЧАС МАЛОІНВАЗИВНОГО ЛІКУВАННЯ АБСЦЕСІВ ПЕЧІНКИ

Причинами абсцесів печінки є патогенні бактерії, віруси, паразити (ехінокок), пізні, важкі хірургічні операції на печінці, релапаротомія, токсичні продукти метаболізму промислових відходів, травми, токсичні лікарські препарати тощо. У дослідженні вивчалися результати лікування 140 пацієнтів, які перенесли малоінвазивне хірургічне лікування абсцесу печінки в період з 2015 по 2025 рік. Серед них 86 були жінками (61,4 %) і 54 – чоловіками (38,6 %). Абсцес печінки було виявлено в правій частці у 108 (77,1 %) пацієнтів та в лівій частці у 32 (22,9 %) пацієнтів. Серед запропонованих нами малоінвазивних методів катетеризація є найефективнішим методом. Постійне використання дренажного катетера вважається безпечним та ефективним методом. Оскільки місцеве застосування та внутрішньовенне введення оптимізованої дози розчину озону протягом 5–7–10 днів є простим, легким, економічно доцільним та ефективним методом, відсоток пацієнтів, які одужали, збільшився в 1,3–1,6 рази, кількість ускладнень знизилася в 1,1–1,5 рази, смертність зменшилася в 1,4–1,8 рази, а кількість ліжко-днів і фінансові витрати скоротилися.

Ключові слова: абсцес печінки, малоінвазивна хірургія, оптимізована доза озонного розчину.

Minimally invasive laparoscopic, percutaneous puncture aspiration and (biopsy) drainage (catheter) methods of treatment of liver abscesses (LA) are among the urgent problems of modern surgery. Despite the widespread use of minimally invasive methods in surgery, surgeons' attitudes towards these methods are far from unambiguous. Despite the high assessment of the results of LA interventions under the control of laparoscopic imaging, ultrasound and CT, indications and contraindications to these methods, as well as the characteristic features of their complications, remain an urgent issue. [1, 2, 5, 9].

To increase the effectiveness of minimally invasive methods, there are traditional methods for the elimination of intraoperative and postoperative pathological cavities. Methods of local (drainage) and intravenous (systemic) administration with an optimized dose of ozone solution have been proposed to improve the effectiveness of minimally invasive surgical treatment of hollow liver formations. Numerous positive effects of ozone therapy on the body are known in medical science. It enhances microcirculation in the liver and tissues, accelerates the recovery of hepatocytes. Ozone therapy improves the body's oxygen supply, accelerates the process of hematopoiesis (erythrocytes, platelets, leukocytes, lymphocytes, monocytes) and interferon synthesis,

lowers blood sugar levels, and activates metabolism. Ozone solution has antibacterial, antiviral, antifungal, antiparasitic and other positive effects to reduce the pathogenicity of micro organisms. Highly effective results have been achieved by optimizing the systemic or local dose of ozone therapy for laparoscopic, percutaneous needle aspiration and percutaneous catheterization of LA, developing new scientific experience in minimally invasive operations and an algorithm of surgical treatment methods, and applying it to minimally invasive operations) [3, 5, 6, 9].

Modern advances in interventional radiology allow minimally invasive interventions to replace open surgical procedures. A review of the literature on this topic showed that with minimally invasive LA removal, complications amount to 12.8–28.3 %. The incidence of liver abscess formation after repeated and complex surgical operations reaches 12.0–27.5 %. LA accounts for 10.0–34.2 % of all intra-abdominal complications, and after relaparotomy they occur in 0.24–0.58 % of cases. Modern advances in interventional radiology make it possible to replace open surgical procedures with minimally invasive procedures. [4, 6, 10–12].

Minimally invasive treatments can become an alternative to open surgery to preserve health. After

intermittent and continuous minimally invasive interventions, along with antibiotics, antiseptics, lower and upper laser drainage therapy, an optimized dose of ozone solution is also used. The widespread use of minimally invasive endovisual surgical technology in clinical practice has opened a priority area in the surgical treatment of liver abscesses [1, 3, 5, 7, 8].

The purpose of the study was to develop a new surgical technique for local and intravenous administration of an optimized dose of ozone solution during laparoscopic, percutaneous puncture aspiration or percutaneous catheterization.

Materials and methods. The research was conducted at the Medical Faculties of Kocaeli University, at the Scientific Surgery Center named after Academician M.A. Topchubashov, at the Medical Faculty of Nakhchivan State University and the Surgical Department of the Hospital of the Nakhchivan Autonomous Republic in 2015–2025. The study examined the treatment results of 140 patients who underwent minimally invasive surgical treatment of liver abscess. There were 86 women (61.4 %) and 54 men (38.6 %) among them. In 108 (77.1 %) patients, liver abscess was localized in the right lobe, in 32 (22.9 %) patients – in the left lobe. A single abscess was observed in 104 (74.3 %), multiple abscesses in 36 (25.7 %) patients. The average age of the patients was 54.1 ± 16.8 years.

The study of patients with liver abscess was divided into two groups: percutaneous puncture aspiration, biopsy, and laparoscopic or percutaneous drainage catheterization. The clinical and anamnestic information of patients, duration of hospital stay, treatment results, recovery, complications, relapses and mortality were analyzed. Minimally invasive operations were performed under the control of laparoscopic imaging, ultrasound and CT. The causes of liver abscesses are pathogenic bacteria, viruses, parasites (echinococcus), late, severe liver surgery, relaparotomy, toxic products of industrial waste metabolism, injuries, toxic drugs, etc. (Fig. 1).

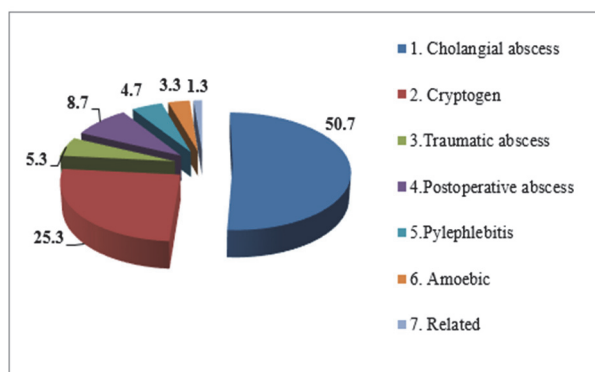


Fig. 1. Etiology of liver abscesses.

All patients underwent general and biochemical blood tests. The pathogenicity of the abscess crops was determined to be gram-positive or gram-negative. Microscopy was performed first. A smear

was prepared from the grown colonies on a nutrient medium and stained using the Gram method. Gram-positive bacteria (purple) or gram-negative (pink after contrast staining with safranin). Thus, we have obtained a conclusion about pathogenicity. Then the sowing was carried out. If microscopy has revealed a probable pathogen, the material is transplanted onto selective media (for example, yolk-salt agar for staphylococcus or blood agar for a wider spectrum). This is necessary to isolate a pure culture and accurately identify the species.

The technique of the proposed method of ozone therapy. In the proposed method, a puncture needle is inserted through the liver at a distance of 0.8–1.2 cm at different angles from the cavity-forming lesion, preventing the contents from entering the peritoneal cavity. This approach allows for a complete puncture-aspiration of the contents of the abscess and effective drainage of the cavity. An ozonated 0.9 % NaCl suspension consisting of finely dispersed aerosols with a particle size from 0.5 to 10 microns is obtained using a specialized device, an IUP-01 M ultrasonic nebulizer designed to produce fine aerosols with a volume of 50.0 ml. Saline solution and ozone-oxygen mixture at a concentration of 5000 micrograms/l are supplied using the Medozons VM device (AOT-N-01-Arz-01/1). The outlet of the device is connected by a polyvinyl tube to a catheter inserted into the residual cavity.

Protocol of ozone therapy. The Medozon-4MP-02 device. At the first stage, a finely dispersed suspension of the ozonated solution is injected into the residual cavity of the abscess through a transducer using 150–200 ml of NaCl at a concentration of 3–5 micrograms / l for 20–30 minutes. At the same time, 250–400 ml of 0.9 % NaCl solution with an ozone concentration of 5–10 micrograms / l is administered intravenously. Ozonated saline solution is used as a finely dispersed phase with a particle size from 0.5 to 10 microns, which ensures the active penetration of the antiseptic solution into the cavity of the abscess. In both traditional and modern procedures, gauze swabs and drains soaked in ozonated solution are placed in the abscess cavity and re-moistened daily for 2–3 days before removal.

Ethical principles were observed in accordance with the Helsinki Declaration (2013). All personal data of the patients has been depersonalized.

The statistical analysis was carried out using the statistical software SPSS 12.0. Written and analytical statistical data were used. Quantitative variables were selected using two options. Student's t-test – for independent samples, where it was necessary, for neural variances or for variables of the Mann-Whitney U-test, as a rule, it was not necessary. Categorical variables were analyzed using the x-quadrant test. All statistical tests were conducted at a statistical level of 97–99 %.

Results of the study. A comparative analysis of the results of minimally invasive interventions was

carried out to study scientific and practical experience and improve new effective treatment methods. When comparing the treatment of 118 patients in the groups of percutaneous puncture and aspiration needle (biopsy), percutaneous drainage catheterization (PCD) and laparoscopic catheterization, we obtained the following results. During the study, percutaneous puncture aspiration was possible in 22 (17.2 %) of 34 patients for the first time, in 9 (5.5 %) for the second time, and in 3 (2.3 %) for the third time. Treatment with a percutaneous drainage catheter was performed in 46 (35.9 %) of 56 patients for the first time, and in 10 (7.8 %) for the second time. Percutaneous drainage catheterization was performed in 10 (7.8 %) of 56 patients for the second time, and laparoscopic surgery with a drainage catheter was performed in 30 (23.4 %) patients. In 30 (23.4 %) patients, drainage catheterization was performed under laparoscopic control.

All patients included in the randomization underwent percutaneous aspiration biopsy for abscesses with a diameter of 50 mm or less. For abscesses with a diameter of 50 mm or more, PCD and drainage with laparoscopic video imaging and catheterization were successfully performed. The patients were treated with transduction for 3–5 days, 7–10 days for abscess cavities with a diameter of more than 10 cm, and systemic administration of an optimized dose of ozone solution (5–8 mg/l) for 10–12 days. Continuous PCD and aspiration with laparoscopic video imaging and catheterization with drainage were performed in 86 (67.2 %) patients. Based on the results of seeding and determination of the sensitivity of pus, 12 patients in the drainage group and 5 patients in the needle group underwent trans-drainage (local) ozone therapy for 12 days. Of the 18 patients who did not respond to repeated aspiration after the first attempt, 16 had a successful outcome after the second attempt. In 2 patients, the result was positive after the third attempt. Treatment of 1 patient, with no positive results after 3 attempts, was discontinued. 86 (67.2 %) patients achieved successful recovery using a drainage catheter. In the group with percutaneous needle puncture, 2 patients underwent more than 3 procedures with negative results. Periodic aspiration biopsy was successful in patients with an abscess diameter of 50 mm or less. However, this treatment was unsuccessful in all 3 patients with multichannel abscesses. In 4 out of 6 patients with multichannel abscesses, a drainage catheter was inserted twice because drainage was insufficient on the first attempt. The total duration of drainage catheter retention ranged from 3 to 25 days, with an average of 11.0 ± 6.4 days. In 31 out of 32 patients with percutaneous puncture-aspiration of the liver abscess cavity for the first, second and third time, a positive effect was obtained due to successful ozone therapy. 29 patients recovered, 2 had complications, and 1 patient died. With the method of treatment using a percutaneous drainage catheter

(PCD) and catheterization with laparoscopic imaging, 92 patients out of 96 patients recovered, complications occurred in 3 patients, and 1 patient relapsed.

Of the 140 patients, 128 (91.4 %) had complete resorption at week 4–5, and treatment was successfully completed. In 6 (4.3 %) patients who received treatment, the abscess cavity decreased and decreased by 50 % at 8–10 weeks, in 1 (0.8 %) patient, the abscess did not completely resolve at 5–6 months, and 1 (0.8 %) patient died. The final results of the patients were also evaluated positively by ultrasound and CT scans performed 6 months after treatment, and the treatment was successfully completed. The length of stay in the clinic between the groups did not significantly differ in both groups (Mann-Whitney U-test, $Z = -0.02$; $p = 0.98$).

No serious complications, such as bleeding or sepsis, were observed after the procedures in both groups. Excellent treatment results were achieved using an optimized dose of ozone solution in both groups. We concluded that PCD is more effective than percutaneous needle aspiration, laparoscopic catheterization, and percutaneous needle-puncture aspiration (biopsy).

If a percutaneous aspiration biopsy fails after the second attempt, treatment should be discontinued. The results of a randomized trial of 128 patients with purulent liver abscesses show that repeated percutaneous puncture drainage should be continued until clinical improvement occurs or the abscess cavity is scarred and reduced. We consider percutaneous needle aspiration performed for the third time after the second attempt to be ineffective. Success after the third attempt may be effective in only one out of 10 patients, and subsequent aspiration biopsy may be successful in very few cases. Our study shows that repeated percutaneous aspiration and percutaneous catheterization are effective in cases of liver abscesses with a diameter of 50 mm or less.

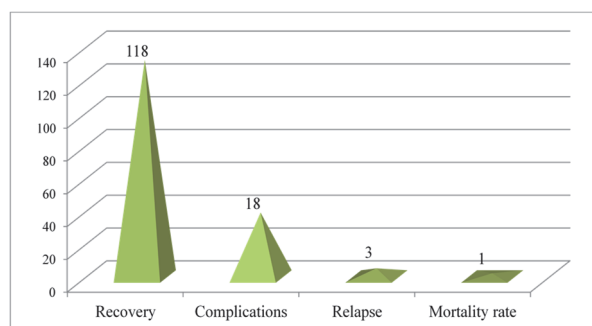


Fig. 2. Graphic representation of the quantitative indicator of the consequences of the conducted therapeutic measures.

As can be seen from Fig.2, when using a percutaneous puncture-aspiration needle of the liver abscess cavity, 29 out of 32 patients recovered, complications were noted in 2 patients, and 1 patient died. During treatment using a percutaneous drainage catheter (PCD) and laparoscopic catheterization, 92

out of 96 patients recovered, complications were noted in 3 patients, and 1 patient died. Of the 140 patients, 118 (84.5 %) had complete resorption at week 6–8, and treatment was successfully completed. In 3 (2 %) patients who received treatment, the abscess cavity decreased and shortened by 50 % at week 10–12, in 1 (0.8 %) patient the abscess did not resolve, and at month 5–6 the patient died.

We suggest prescribing an optimized dose of ozonated solution for laparoscopic and percutaneous operations. In the elimination of LA, complete obliteration of cavities (volume reduction) has been proven in scientific studies on morphological, laboratory and radiological parameters. This method fully complies with the principle of "maximum success with minimal complications." The elimination of liver abscesses and the achievement of complete obliteration of the cavity have been proven by morphological, laboratory and radiological diagnostic methods. We have used ozone therapy to eliminate liver abscesses in more than 180 patients.

Discussion. In addition to traditional procedures with drainage irrigation, the use of local and intravenous doses of optimized ozonated solution increases the effect of treatment and shortens the length of hospital stay. We concluded that the use of Pigtail catheterization as well as percutaneous needle aspiration improves the clinical outcome in patients with abscess volume >150 ml. Pigtail catheterization is a better method of intervention than percutaneous needle aspiration in patients with abscess volume >200–250 ml. Our opinion coincides with the opinion of the authors Prasad S, et al. [8].

All patients included in the randomization were initially treated with broad-spectrum antibiotics of the IV generation at a dose of 1 g twice a day (every 12 hours). [2, 4, 5, 7, 8].

Most authors prefer continuous drainage catheters, as this method of treatment is considered safe and effective in the treatment of liver abscesses [1, 3, 5, 8, 9]. The continuous method is considered safe and effective [2, 4, 5, 8, 9].

Conclusion

Thus, in the minimally invasive methods we propose, catheterization is the best and more effective method. Continuous use of a drainage catheter is considered a safe and effective method. Since topical application of an optimized dose of ozonated solution and intravenous administration for 5–7 to 10 days is simple, easy, cost-effective and effective, the percentage of recovery increased by 1.1 to 1.5 times, complications decreased by 1.3 to 1.7 times, mortality decreased by 1.7 to 2.1 times, bed days and financial costs decreased.

References

1. Ahmed M, Alam J, Hussain S, Aslam M. Prospective randomized comparative study of percutaneous catheter drainage and percutaneous needle aspiration in the treatment of liver abscess. *ANZ J Surg*. 2021 Mar;91(3):E86-E90. doi: 10.1111/ans.1646.
2. Ali M, Imran A, Ismail M, Khan S, Ibrahim M. Comparison of effectiveness of open drainage and percutaneous needle drainage of pyogenic liver abscess. *Pak J Surg*. 2019;35(2):125–31.
3. Bansal A, Bansal AK, Bansal V, Kumar A. Liver abscess: catheter drainage v/s needle aspiration. *Int Surg J*. 2016;2:20–25. <https://www.ijurgery.com/index.php/ij/article/view/476>.
4. Bababayli E.Yu. The choice of the treatment of abdominal abscesses in adult patients. *World of Medicine and Biology*. 2023; 2 (84):23-27. DOI 10.26724/2079-8334-2023-2-84-23-27.
5. Kulhari M, Mandia R. Prospective randomized comparative study of pigtail catheter drainage versus percutaneous needle aspiration in treatment of liver abscess. *ANZ J Surg*. 2019 Mar;89(3):E81-E86. doi: 10.1111/ans.14917.
6. Lin JW, Chen CT, Hsieh MS, Lee IH, Yen DH, Cheng HM, Hsu TF. Percutaneous catheter drainage versus percutaneous needle aspiration for liver abscess: a systematic review, meta-analysis and trial sequential analysis. *BMJ Open*. 2023 Jul 30;13(7):e072736. doi: 10.1136/bmjopen-2023-072736.
7. Losie JA, Lam JC, Gregson DB, Parkins MD. Epidemiology and risk factors for pyogenic liver abscess in the Calgary Health Zone revisited: a population-based study. *BMC Infect Dis*. 2021 Sep 10;21(1):939. doi: 10.1186/s12879-021-06649-9.
8. Prasad S, Agarwal A, Kumar S, Kumar B. Comparative study between percutaneous needle aspiration vs pigtail catheter in liver abscess drainage. *Eur J Mol Clin Med*. 2022;9:1439–1445. <https://www.ejmcm.com/archives/volume-9/issue-1/1219>.
9. Singh P, Tapasvi C, Kaur R, Aggarwal S, Nagpal N, Kaur R. Prospective randomized comparison of ultrasound-guided percutaneous needle aspiration with percutaneous catheter drainage of liver abscesses. *J Med Sci* 2019; 39(2):67-73. DOI:10.4103/jmedsci.jmedsci_74_18.
10. Yin D, Ji C, Zhang S, Wang J, Lu Z, Song X, Jiang H, et al. Clinical characteristics and management of 1572 patients with pyogenic liver abscess: A 12-year retrospective study. 2021 Apr;41(4):810-818. doi: 10.1111/liv.14760.
11. Vakamacawai E, McCaig E, Waqainabete I, Cox MR. Amoebic Liver Abscesses in Fiji: Epidemiology, Clinical Presentation and Comparison of Percutaneous Aspiration and Percutaneous Catheter Drainage. *World J Surg*. 2020 Mar;44(3):665-672. doi: 10.1007/s00268-019-05274-7.
12. Yang J, Zhang L, Wang Q. Pyogenic liver abscess after Milligan-Morgan hemorrhoidectomy. *J Surg Case Rep*. 2024 Jun 3;2024(6):rjae388. doi: 10.1093/jscr/rjae388.

Conflict of interest. The authors have no conflicts of interest to declare.

ORCID: Bababayli E.Y. <https://orcid.org/0009-0008-3539-9652>, Bababayli N.E. <https://orcid.org/0009-0003-9151-6562>.

Article received: 19.05.2025