

и у 33,3% больных В-клеточной хронической лимфоцитарной лейкемией и множественной миеломой. Гиперлейкоцитоз периферической крови и увеличение активности щелочной фосфатазы сыворотки крови можно расценивать как фактор риска опухолевой инфильтрации печени.

**Ключевые слова:** хронические лимфопролиферативные заболевания, опухолевая инфильтрация печени, биохимические печеночные тесты.

Стаття надійшла 10.12.18 р.

33.3% of patients with B-cell chronic lymphocytic leukaemia and multiple myeloma. Peripheral blood hyperleukocytosis and increased serum alkaline phosphatase activity can be considered as a risk factor for liver tumor infiltration.

**Key words:** chronic lymphoproliferative diseases, tumor liver infiltration, biochemical liver tests.

Рецензент Катеренчук І.П.

DOI 10.26724/2079-8334-2019-3-69-118-122

UDC 340.624.1: 616-001.45

V.D. Mishalov<sup>1</sup>, O.Yu. Petroshak<sup>1</sup>, T.V. Hoholyeva<sup>1</sup>, O.O. Gurina<sup>1</sup>, V.I. Gunas<sup>2</sup>

<sup>1</sup>Shupyk national medical academy of postgraduate education, Kyiv

<sup>2</sup>National Pirogov Memorial Medical University, Vinnytsya

## FORENSIC ASSESSMENT OF GUNSHOT INJURIES IN MAIDAN NEZALEZHNOSTI PROTESTERS

e-mail: k-sme@nmapo.edu.ua

Over the last 5 years, the number of gunshot injuries in Ukraine has increased. The information about the peculiarities of bodily harm in the protesters of the Maidan Nezalezhnosti in Kyiv in 2014 remains relevant. The purpose of the study was to analyze the peculiarities of injuries sustained by Euromaidan protesters on February 18-20, 2014. The material of the study was archival materials ("Specialist conclusions") of the Department of Forensic Medicine of the Shupyk national medical academy of postgraduate education with the results of the investigation of injuries of 322 injured protesters on February 18-20, 2014 in Kyiv. Research methods were used: anthropometric, morphometric and photographic. The largest number among the victims made up men with gunshot injuries, caused by elastic bullets and a buckshot, lead meal and a buckshot, a 12 mm "Blondo" type metal ball; thermal, chemical burns; contusions, loss of vision and hearing, traumatic amputations of the fingers caused by stun grenades. There were injuries caused by police batons, sticks, fists and feet. The nature, volume and predominant localization of the damages (lower extremities and head) indicate that the stun grenades were intentionally and artificially completed with additional striking components. Light injuries were dominated by degree of severity. Among the injuries in 322 victims of the Euromaidan protesters during the events of February 18-20, 2014, the largest number consisted of manifestations of gunshot injuries: bruises, bleeding, wounds caused by elastic bullets and a bullet to a "non-lethal" weapon and lead buckshot and buckshot, 12mm "Blondo" metal ball; thermal, chemical burns, contusions, loss of vision and hearing, traumatic amputations of the fingers caused by stun grenades.

**Key words:** forensic medicine, bodily injury, gunshot injury.

*The work is a fragment of the research project "Gunshot trauma: morphological, medical and forensic features of injuries and criteria for their formation" (State registration number 0115U002357).*

Mass riots, public disobedience and other conflicts are taking place in many countries around the world and are becoming more frequent. Practically all such events lead to clashes of protesters with law enforcement agencies or among themselves. In the following, the description, analysis and conclusion of the nature of the injuries falls on the shoulders of forensic institutions dealing with numerous work problems, such as an extremely large number of victims, the inability to accurately determine the circumstances of the case, etc. [10, 12].

However, in most cases, forensic institutions deal with bodily injury caused by mostly blunt objects (police batons, etc.). Cases of use of firearms are rarer and insufficiently studied, because atypical firearms (traumatic weapons, special weapons, etc.) are usually used.

The problem of gunshot injuries has been and continues to be extremely pressing among other problems of society. Not only forensic experts, surgeons, traumatologists, but also law enforcement, arms manufacturers and other specialists are involved in its decision. In particular, the number of gunshot wounds has increased several times in the past 5 years, both as a result of the social tension in 2014 on Maidan Nezalezhnosti and War in Donbass, including the consequences of an explosive injury [2]. According to the research V.D. Mishalov, V.V. Voichenko, V.T. Bachinsky, G.F. Kryvda [4] in Kyiv, it increased by 4-6 times. In addition to the study of the impact of firearms on the human body, an important area of expertise is forensic assessment of damage to human clothing, which can provide information, in particular, on the distance of a shot and identify firearms [1, 3]. Although a great deal of domestic and foreign scientific research has been devoted to the firearm trauma [7, 8, 11, 13, 15, 16], some aspects, in particular, of its morphological manifestations, need to be assessed now.

It's been the fifth year since the Euromaidan, but consequences of violence against Euromaidan protesters have not lost their relevance today, in 2019, as the perpetrators of the crime have not been fully identified and punished. While hundreds of people have suffered multiple injuries – from being beaten with

police batons to gunshot wounds – are known and are waiting for justice. Therefore, information on the features of the gunshot injury among the protesters of Maidan Nezalezhnosti in Kyiv in 2014 remains relevant.

**The purpose** of the study was to analyze the peculiarities of injuries caused by firearms, stun grenades and blunt objects in the protesters of Maidan Nezalezhnosti, which were caused during the period 18-20 February 2014.

**Materials and methods.** The material of the study was archival materials ("Specialist conclusions") of the Department of Forensic Medicine of the Shupyk national medical academy of postgraduate education, which contained documentary recording of injuries to 322 people who were injured during active events on the Maidan Nezalezhnosti in Kyiv, February 18-20, 2014. To achieve this goal, the following research methods were used: anthropometric, morphometric, photographic. *Anthropometric and morphometric* methods were used to fix the size and description of the victims of injuries from abrasions to fractures (with the help of text and folded schemes). The scheme is a universal visual image, a kind of model that succinctly absorbs, integrates and clearly demonstrates a significant amount of forensic information and captures a number of other various facts, allows to come to the right scientifically valid convincing expert conclusions. Diagrammatic representation of bodily injury is a logical complement to forensic photography and thus helps to objectify forensic research. *Photographic research* has been used to capture various forms of personal injury. In the study of their peculiarities, a photographic method was used in which, according to the rules of forensic photography, a selective photographing of research objects was carried out with a digital camera "Canon D90", allowing the possibility of a matrix – 7.1 megapixels. Analysis and production of the illustrations were carried out using a personal computer with a Pentium-4 processor. The results of the survey were recorded in the protocol part of the "Specialist conclusions".

**Results of the study and their discussion.** By researching archival materials of the Department of Forensic Medicine of the Shupyk national medical academy of postgraduate education which were received during the examination of the victims during the period from February 24 to March 6, 2014 on Maidan Nezalezhnosti, namely – "Specialist conclusions", which indicated the type of trauma, the prescription and the mechanism of its formation, the severity of bodily injuries, photo illustrations of injuries were established peculiarities of bodily harm in Euromaidan protesters of February 18-20, 2014. Subsequently, this document was the basis for appealing to the investigative and judicial authorities, for the appointment of forensic expertise and the opening of criminal proceedings against and the fact of the crime.

Of the 322 Euromaidan protesters surveyed, 297 were men - the largest amount among the victims. A much smaller proportion of those surveyed were women – 25 victims.

In general, each victim was assigned different types of injuries: bruises, abrasions, wounds, bone fractures, burns, various gunshot injuries, traumatic amputation of the fingers.

Regarding damage localization, the most common sites of injury localization were the lower extremities (found in 165 people) and the head (found in 134 people).

The greatest amount of damage was caused by an explosive injury. Numerous wounds of the head, upper extremities were caused by stun grenade, but the greatest number of them appeared at the lower extremities due to the formation of fragments from the shell of the grenades and additional striking components (nails, nuts, stones, etc.) that were added by "law enforcement officers" (Fig. 1-2). In addition, grenade breaks also led to thermal, chemical burns, contusions, loss of vision and hearing, which, in general, harmed the health of the largest number of people – 133. A significant number of victims – 55 received gunshot wounds from elastic bullets and buckshot by tools of shock-traumatic ("non-lethal") action in different parts of the body and extremities (Fig. 3), as well as lead meal and buckshot of firearms (Fig. 4 a).

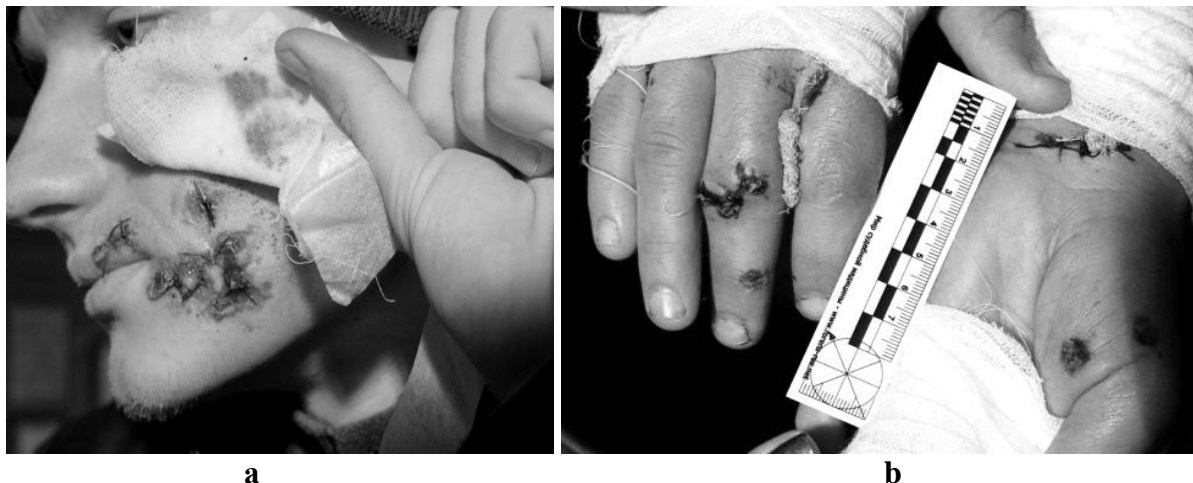

Fig. 1. Damage of head (a) and hands (b) caused by additional striking elements and debris from the body of stun grenade.

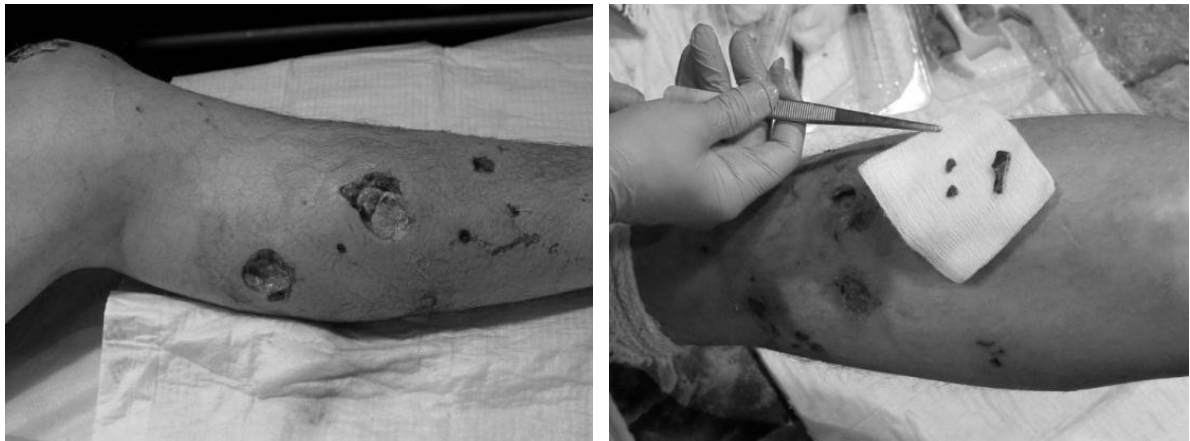

Fig. 2. Damage of the lower extremities caused by additional striking elements and debris from the body of stun grenade.

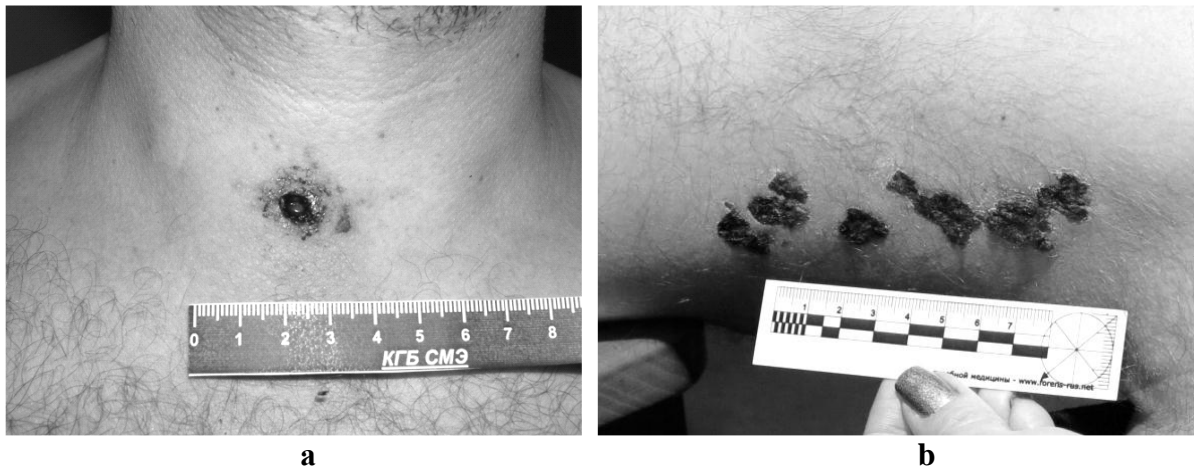


Fig. 3. Gunshot injuries of the neck (a) and hips (b) caused by elastic bullets 9 mm pistol of traumatic shock (non-lethal) action.

There were a few injuries caused by 12mm “Blondo” metal bullets intended to open the door locks and stop the car. (Fig. 5 b).

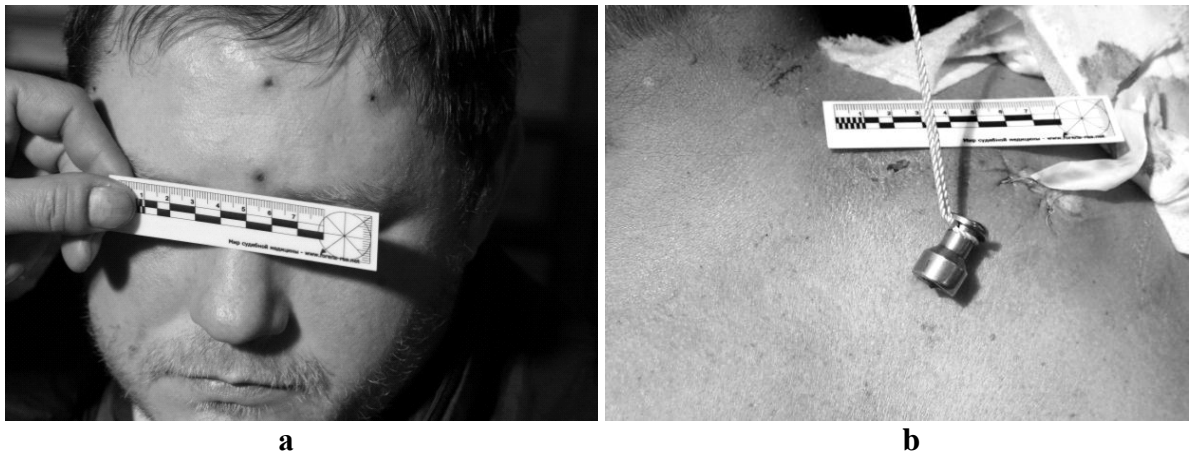


Fig. 4. Gunshot damage of frontal area of head caused by lead meal (a), back injury caused by 12 mm metal bullet of type “Blondo” (b).

It is also necessary to pay attention to injuries sustained by blunt objects: police batons, sticks, fists, legs, etc. Such injuries were identified in 132 victims and rank second place. Two of the victims sustained injuries caused by stabbing objects.

Speaking about the severity of the injuries, it should be noted that the majority of the injuries in the surveyed patients were light injuries and light injuries that caused short-term health disorders. The average severity had 14% of victims and only had 2 severe. This can be explained by the fact that only a part of the victims appealed to us, as the other hundreds of injured protesters with traumatic brain injuries, fractures of the head and limbs, visual disturbances, hearing and other serious injuries, accompanied by long-term health disorders medical care were hospitalized.

Thus, forensic science plays one of the key roles of fixing damages as a result of riots and armed conflicts, and only by further analyzing the data obtained can improve the results of its work and develop new approaches and methods for the collection of material evidence, their processing and, as a result, more complete and qualitative conclusions [5, 6, 9, 14].

### Conclusion

1. The greatest number of injuries in Euromaidan protesters injured during active events on February 18-20, 2014 belongs to a gunshot injury, such as its components: bruising, hemorrhage, wounds caused by elastic bullets and buckshot that belongs to means of shock and traumatic action and bullets, shot pellets and buckshot from firearms, 12 mm "Blondo" metal bullet, thermal, chemical burns, contusions, loss of vision and hearing, traumatic amputations of the fingers caused by stun grenades.

2. The largest number of surveyed Euromaidan protesters made up men - 297 persons, women - 25 persons.

3. The nature, volume, and location of the damage suggested that stun grenades were artificially equipped with additional striking components.

4. The predominant localization of injuries was the lower extremities and the head, and the degree of severity was dominated by light bodily injuries.

### References

1. Bobkov PYu, Lebed MF, Perebetyuk AM, Gunas, VI. Sudovo-medychna kharakterystyka vohnepalnykh poshkodzen shkirozaminnyka pry postrilakh iz pistoleta "Fort-17R". Bukovynskyi medychnyi visnyk. 2019; 23: 51-56. <https://doi.org/10.24061/2413-0737.XXIII.2.90.2019.33> [in Ukrainian]
2. Kozlov SV, Tkachenko OV, Zrozhevskiy RS. Sudovo-medychna kharakterystyka tilesnykh ushkodzen pry kontaktomu vybukhu hranaty F-1. Sud.-med. Ekspertyza. 2016; 1: 78-80. [in Ukrainian]
3. Legin GA, Bondarchuk AO, Perebetyuk AN. Sudebno-meditsinskaya harakteristika vhodnykh otverstiy pri vyistrelakh iz pnevmaticheskogo pulevogo oruzhiya. Sudebno-meditsinskaya ekspertiza. 2015 Mar 1; 58(2): 14-16. <https://doi.org/10.17116/sudmed201558214-16> [in Russian]
4. Mishalov VD, Khokholieva TV, Voichenko VV, Bachynskiy VT, Kryvda HF. Analiz kilkosti osib, shcho zahynuly vnaslidok vohnepalnoi travmy sered naseleння Ukrainy za 2007-2016 rr. Zb. nauk. pr. spivrobitnykiv NMAPO im. P.L. Shupyka. 2018; 30: 591-598. [in Ukrainian]
5. Bodalal Z, Mansor S. Gunshot injuries in Benghazi-Libya in 2011: The Libyan conflict and beyond. the surgeon. 2013 Oct 1; 11(5): 258-263. <https://doi.org/10.1016/j.surge.2013.05.004>
6. Jena AB, Sun EC, Prasad V. Does the declining lethality of gunshot injuries mask a rising epidemic of gun violence in the United States?. Journal of general internal medicine. 2014 Jul 1; 29(7): 1065-1069. <https://doi.org/10.1007/s11606-014-2779-z>
7. Kneubuehl B, Coupland RM, Rothschild MA, Thali M, redakteure. Wundballistik: grundlagen und anwendungen. 3., vollst. überarb. u. erw. Aufl. Heidelberg, Germany: Springer. 2008; 25: 491.
8. Lantz PE, Stone RS, Broudy D, Morgan TM. Terminal ballistics of the 9mm with Action Safety bullet or Blitz-Action-Trauma (BAT) ammunition. J Forensic Sci. 1994; 3: 612-623. <https://doi.org/10.1520/JFS13637J>
9. Martín-Alberca C, Ferrando JL, García-Ruiz C. Anionic markers for the forensic identification of Chemical Ignition Molotov Cocktail composition. Science & Justice. 2013; 1: 49-54. <https://doi.org/10.1016/j.scijus.2012.11.004>
10. Mohammed EM. Forensic Analysis of Firearm Injuries in Fayoum Governorate in the Period from 2011 to 2016. Ain Shams Journal of Forensic Medicine and Clinical Toxicology. 2019; 33: 1-7. DOI: 10.21608/AJFM.2019.27640.
11. Newgard CD, Kuppermann N, Holmes JF, Haukoos JS, Wetzel B, Hsia RY, Wang NE, Bulger EM, Staudenmayer K, Mann NC, Barton ED. Gunshot injuries in children served by emergency services. Pediatrics. 2013 Nov 1; 132(5): 862-870. doi: 10.1542/peds.2013-1350.
12. Obafunwa JO, Faduyile FA, Soyemi SS, Eze UO, Nwana EJ, Odesanmi WO. Forensic Investigation of mass disasters in Nigeria: A review. Nigerian medical journal: journal of the Nigeria Medical Association. 2015; 1: 1-5. doi: 10.4103/0300-1652.149162.
13. Papachristos AV, Wildeman C, Roberto E. Tragic, but not random: The social contagion of nonfatal gunshot injuries. Social Science & Medicine. 2015 Jan 1; 125: 139-150. <https://doi.org/10.1016/j.socscimed.2014.01.056>
14. Peerwani N. The role of a forensic pathologist in armed conflict. Academic forensic pathology. 2017; 3: 370-389. <https://doi.org/10.23907/2017.033>
15. Szwarcwald CL, de Castilho EA. [Mortality by firearms in the state of Rio de Janeiro, Brazil: a spatial analysis]. Rev Panam Salud Publica. 1998; 3: 61-70. DOI: 10.1590/S1020-49891998000900003.

### Реферати

#### СУДОВО-МЕДИЧНА ОЦІНКА ВОГНЕПАЛЬНИХ УШКОДЖЕНЬ У ПРОТЕСТУВАЛЬНИКІВ МАЙДАНУ НЕЗАЛЕЖНОСТІ

Мишалов В.Д., Петрошак О.Ю., Хохольова Т.В.,  
Гуріна О.О., Гунас В.І.

Протягом останніх 5 років в Україні кількість вогнепальних поранень зросла. Актуальною залишається інформація про особливості тілесних ушкоджень у протестувальників Майдану Незалежності

#### СУДЕБНО-МЕДИЦИНСКАЯ ОЦЕНКА ОГНЕСТРЕЛЬНЫХ ПОВРЕЖДЕНИЙ У ПРОТЕСТУЮЩИХ ПЛОЩАДИ НЕЗАВИСИМОСТИ

Мишалов В.Д., Петрошак А.Ю., Хохольова Т.В.,  
Гуріна О.А., Гунас В.И.

В течение последних 5 лет в Украине количество огнестрельных ранений возросло. Актуальной остается информация об особенностях телесных повреждений у протестующих на Майдане Независимости в Киеве, в 2014

у м. Києві у 2014 році. Мета дослідження – аналіз особливостей тілесних ушкоджень, отриманих протестувальниками Майдану 18-20 лютого 2014 р. Матеріалом дослідження були архівні матеріали («Висновки спеціаліста») кафедри судової медицини Національної медичної академії післядипломної освіти з результатами дослідження тілесних ушкоджень 322 потерпілих протестувальників 18-20 лютого 2014 р. у м. Києві. Використовувались методи дослідження: антропометричний, морфометричний; фотографічний і статистичний. Найбільшу кількість серед потерпілих складали чоловіки з вогнепальними ушкодженнями, заподіяними еластичними кулями і картечю, свинцевим шротом і картечю, 12 мм металевою кулею типу «Блондо»; термічні, хімічні опіки; контузії, втрати зору і слуху, травматичні ампутації пальців рук від розриву світло-шумових гранат. Мали місце ушкодження, заподіяні мільцієвськими кийками, палками, кулаками і ногами. Характер, об'єм та переважна локалізація ушкоджень (нижні кінцівки і голова) свідчать про те, що світло-шумові гранати умисно і штучно були укомплектовані додатковими вражаючими компонентами. За ступенем тяжкості переважали легкі тілесні ушкодження. Серед тілесних ушкоджень 322 потерпілих протестувальників Майдану під час подій 18-20 лютого 2014 р. найбільшу кількість складали прояви вогнепальної травми: садна, крововиливи, рани, спричинені еластичними кулями і картечю до «нелетальної» зброї та свинцевим шротом і картечю, 12 мм металевою кулею типу «Блондо»; термічні, хімічні опіки, контузії, втрати зору і слуху, травматичні ампутації пальців рук від розриву світло-шумових гранат.

**Ключові слова:** судова медицина, тілесні ушкодження, вогнепальні ушкодження.

Стаття надійшла 30.12.19 р.

году. Цель исследования – анализ особенностей телесных повреждений, полученных протестующими Майдана 18-20 февраля 2014 года. Материалом исследования были архивные материалы («Заключение специалиста») кафедры судебной медицины Национальной медицинской академии последипломного образования с результатами исследования телесных повреждений 322 пострадавших протестующих 18-20 февраля 2014 г. в Киеве. Использовались методы исследования: антропометрический, морфометрический; фотографический и статистический. Наибольшее количество среди пострадавших составляли мужчины с огнестрельными повреждениями, причиненными эластичными пулями и картечью, свинцовой дробью и картечью, 12 мм металлической пулей типа «Блондо»; термические, химические ожоги; контузии, потери зрения и слуха, травматические ампутации пальцев рук от разрыва свето-шумовых гранат. Имели место повреждения, причиненные милицейскими дубинками, палками, кулаками и ногами. Характер, объем и преимущественная локализация повреждений (нижние конечности и голова) свидетельствуют о том, что свето-шумовые гранаты умышленно и искусственно были укомплектованы дополнительными поражающими компонентами. По степени тяжести преобладали легкие телесные повреждения. Среди телесных повреждений 322 пострадавших протестующих на Майдане во время событий 18-20 февраля 2014 года наибольшее количество составляли проявления огнестрельного травматизма: садины, кровоизлияния, раны, вызванные эластичными пулями и картечью к «не летальному» оружию и свинцовой дробью и картечью, 12 мм металлической пулей типа «Блондо»; термические, химические ожоги, контузии, потери зрения и слуха, травматические ампутации пальцев рук от разрыва свето-шумовых гранат.

**Ключевые слова:** судебная медицина, телесные повреждения, огнестрельные повреждения.

Рецензент Гаврилюк А.О.

DOI 10.26724/2079-8334-2019-3-69-122-127

UDC: 572.087:612.13:796.071

V.M. Moroz, O.P. Khapitska, L.A. Sarafinyuk, S.Y. Iaremyn, O.V. Androshechuk  
National Pirogov Memorial Medical University, Vinnytsya

## CORRELATION OF THIGH RHEOVASOGRAPHIC INDICES WITH CONSTITUTIONAL CHARACTERISTICS IN VOLLEYBALL PLAYERS OF ECTO-MESOMORPHIC SOMATOTYPE

e-mail: lsarafinyuk@gmail.com

It has been established that volleyball players with ecto- mesomorphic somatotype have numerous statistically significant correlations between the parameters of the thigh rheovasogram and anthropometric and somatotypological indices. The most numerous and strongest correlations has been found between the indices of the external composition of the body, in particular, longitudinal, transverse, circumferential dimensions, thickness of the skin and fat folds, somatotypological characteristics and temporal, amplitude parameters of the rheogram, hemodynamic indices and arterial tone indices, with predominant direct moderate and strong correlations.

**Keywords:** correlation, thigh rheovasography, anthropometry, somatotyping, ecto-mesomorphic somatotype, volleyball players.

*The work is a fragment of the research project "Features of the hemodynamic rates according to the parameters of body composition in athletes of various sports", state registration No.0115U004045.*

Currently, the somatotypological approach is widely used during sports selection, which is relevant in identifying prognostic signs of prospectivity for achievements in various sports [8, 11]. In this case, a certain set of local constitutional features is traditionally taken into account, which is determined by the external morphological component of the constitution [7, 14]. It is known that representatives of some constitutional types differ not only in the external composition of the body, but also by the features of the cardiovascular, nervous, endocrine system [4]. It has been proved that morphofunctional features of the