

Реферати

**ХАРАКТЕР УЛЬТРАСТРУКТУРНИХ ЗМІН,  
ЗУМОВЛЕНИХ ОРХОЕПІДИДИМИТОМ,  
В ЯЄЧКУ І ЕЯКУЛЯТІ ЧОЛОВІКІВ**

Глодан О.Я., Грицуляк Б.В., Грицуляк В.Б.,  
Івасюк І.І.

В 14 біоптатах яєчка неплідних чоловіків віком 22-35 років, що перенесли орхоепідидиміт, досліджено характер ультраструктурних змін та їх вплив на показники еякуляту. Встановлено деформацію і пікноз ядер, нерівномірне розширення перинуклеарного простору, вакуолізацію цитоплазми, гомогенізацію крист мітохондрій, розширення цистерн ендоплазматичної сітки та елементів комплексу Гольджі в ендотеліоцитах гемокапілярів, міоїдних клітинах власної оболонки звивистих сім'яних трубочок, підтримувальних епітеліоцитах, сперматоцитах і сперматидях, які супроводжувались в еякуляті зменшенням вдвічі концентрації сперматозоїдів в 1 мл, збільшенням у 3 рази кількості патологічних форм та зниженням їх рухливості.

**Ключові слова:** яєчко, орхоепідидиміт, клітини сперматогенного епітелію, еякулят.

Стаття надійшла 24.05.2019 р.

**ХАРАКТЕР УЛЬТРАСТРУКТУРНИХ  
ИЗМЕНЕНИЙ В ЯИЧКЕ И ЭЯКУЛЯТЕ МУЖЧИН,  
ОБУСЛОВЛЕННЫХ ОРХОЭПИДИДИМИТОМ**

Глодан О.Я., Hrytsuliak Б.В., Грицуляк В.В.,  
Ивасюк И.И.

В 14 биоптатах яичка бесплодных мужчин в возрасте 22-35 лет, перенесших орхоэпидидимит, исследован характер ультраструктурных изменений и их влияние на показатели эякулята. Установлены деформация и пикноз ядер, неравномерное расширение перинуклеарного пространства, вакуолизация цитоплазмы, гомогенизация крист митохондрий, расширение цистерн эндоплазматической сети и элементов комплекса Гольджи в эндотелиоцитах гемокапилляров, миоидных клетках собственной оболочки извитых семенных трубочек, поддерживающих эпителиоцитах, сперматоцитах и сперматидях, которые сопровождалась в эякуляте уменьшением концентрации сперматозоидов вдвое в 1 мл, увеличением в 3 раза количества патологических форм и снижением их подвижности.

**Ключевые слова:** яичко, орхоэпидидимит, клетки сперматогенного эпителия, эякулят.

Рецензент Єрошенко Г.А.

DOI 10.26724/2079-8334-2020-1-71-176-180

UDC 616.314.18:616.314-002

**О.В. Hrynyshyn, N.M. Dydyk, B.M. Filenko<sup>1</sup>**  
**Danylo Halytsky Lviv National Medical University, Lviv**  
**<sup>1</sup>Ukrainian Medical Stomatological Academy, Poltava**

**EXPERIMENTAL MORPHOLOGICAL STUDY OF DENTAL PULP LESIONS AT DIFFERENT STAGES OF DENTAL CARIES**

e-mail: borius007filenko@ukr.net

Numerous studies show that in the structure of the affection of deciduous teeth by dental caries, a high percentage of complicated dental caries is observed. Paper was aimed at the study of morphological lesion of the dental pulp in experimental dental caries of various severity in rats with theoretical rationale of the principles of treatment of pulpitis. 50 outbred albino male rats were involved into study. Experimental dental caries in rats was induced by special cariesogenic diet. At the first stage, the depth of carious lesions of the enamel and dentin was measured. The second stage was performed on decalcified blocks of teeth, serial sections were made from the resulting blocks, stained with hematoxylin and eosin. It revealed the potential occurrence of more frequent complications in the conservative treatment of deep carious lesions of approximal surfaces in comparison with deep lesions of chewing surfaces. Dental pulp carious lesion depends not only on the degree of carious process, but also on its localization, which should be taken into account when choosing the optimal method of treatment of dental caries, which also prevents the development of its complications.

**Key words:** experimental caries, tooth pulp, morphology.

*The work is a fragment of the research project "Morphogenesis patterns of organs, tissues and vascular-nerve formations in normal, in pathology and under the influence of external factors", state registration No. 0118U004457.*

Notwithstanding the rapid development of dental science, the emergence of the advanced technologies and capabilities, the high prevalence of dental caries, especially in childhood, has prompted the WHO to include it into the six global contemporary diseases. Numerous studies show that in the structure of the affection of deciduous teeth by dental caries, a high percentage of complicated dental caries is observed [2, 3].

The main feature of the dental caries occurrence in deciduous teeth is rapid development of the pathological process. This is due to a thin enamel of deciduous teeth, a smaller volume of dentin, the presence of low-mineralized zones in it, which reach the pulp by broad bands in the form of interglobular dentin.

The dentin pulp complex responds to the microorganism's invasion into deep layers of the dentin by the formation of tertiary dentine, which is a protective barrier, since it reduces the diffusion of the latter in the direction of the pulp [7, 10]. However, the feature of the pulp of deciduous teeth is in its insignificant functional ability to produce dentin substitute, due to the minimum expressed protective and adaptive properties. At the same time, according to [9] the deciduous teeth pulp is quite often in a state of chronic

inflammation, which is represented by a chronic inflammatory exudate, including lymphocytes, macrophages and plasma cells. In some cases pulp recovery is possible, which, however, is a long-term process and depends on many factors, such as the overall state of the child's health, virulence of microorganisms, the possibility of the regenerative potential of the pulp, etc. Therefore, predicting lesions in pulp in the presence of dental caries, especially in the deciduous teeth, is quite difficult [1, 12].

**The purpose** of the paper was to study morphological lesion of the dental pulp in experimental dental caries of various severity in rats with theoretical rationale of the pulpitis treatment principles.

**Materials and methods.** The total of 50 outbred albino male rats aged  $\approx 30$  days weighing 35-40 g were involved into the study. Experimental dental caries in rats was induced by special cariesogenic diet, including: 54.0% saccharose, 18.5% cow cheese, washed under tap water and dried to solid state; 18.5% white bread crackers; 5% sunflower oil; 4 g sodium chloride and 1 dragee of the multivitamin complex "Undevit" per 100 g of feed. Under conditions of the diet, the animals were kept for 168 days with a gradual withdrawal from the experiment by the method of chloroform anesthesia overdose. The biological material was taken on the 28, 42, 56, 84, 98, 112, 126, 140, 154 and 168th day of the experiment and in the amount of 5 animals at each stage. Animal housing and experiments on them have been carried out in compliance with requirements of international principles of the "European Convention for the Protection of Vertebrate Animals Used for Experimental and Other Scientific Purposes" (Strasbourg, 1985), and "General Ethic Rules for Conducting Experiments on Animals", adopted by the I National Congress on Bioethics (Kyiv, 2001).

Determination of morphological changes in different parts of the tooth was carried out in two stages. At the first stage, the depth of carious lesions of the enamel and dentin was measured, which was carried out on the removed non-decalcified jaws with molar and premolar, affected by caries. At the same time a crown of the tooth was cut with a special diamond cutter and stained histochemically with PAS-Alcian blue. This method enables clear distinction between the enamel, dentin and carious lesions. The second stage was performed on decalcified blocks of teeth. After fixation in 10% neutral formalin and paraffin, serial sections were made from the resulting blocks, stained with hematoxylin and eosin. The obtained preparations were used for study of morphological changes of the dental pulp which were observed at superficial, medium and deep dental caries. Decalcified, not affected by dental caries teeth of 5 rats served as the controls.

**Results of the study and their discussion.** The carious process was observed mainly on molars of experimental animals with varying degrees of damage to enamel and dentin. The enamel caries at the stage of the spot developed mainly on 28-56 days, the medium dentin caries on 70-98 days, deep dentin caries without perforation of the pulp chamber on 112-140 days, deep dentin caries with perforation of the pulp chamber on 154-168 days. The caries process developed on both proximal and chewing surfaces of the molars.

In superficial caries in the coronal region of the pulp a capillary hyperemia in the subodontoblastic plexus was noted with sporadic stasis. The main substance of the loose connective tissue of the central region of the pulp adjacent to the vessels was somewhat loosened, swollen. Between the odontoblasts small gaps were found, which were formed due to moderate edema of the stroma of the peripheral region of the pulp. In the root part of the pulp a moderate hyperemia in capillaries was noted without stasis. No pronounced structural changes in the odontoblasts of the root pulp that were located at the root of the pulp were found (fig. 1).

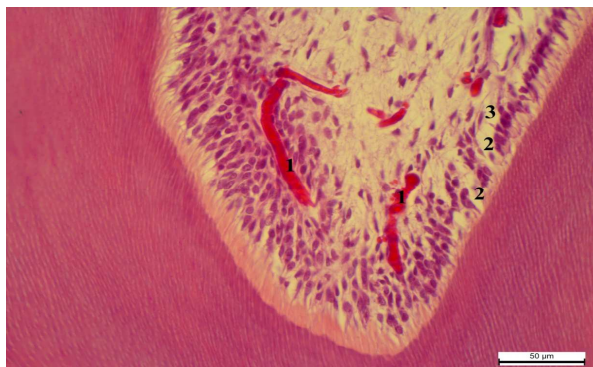

Fig. 1. Coronal pulp lesions in superficial dental caries. H&E stain. 400 $\times$  magnification.

1 – hyperemia in capillaries; 2 – edema in the interodontoblastic space; 3 – edema in subodontoblastic layer of the pulp.

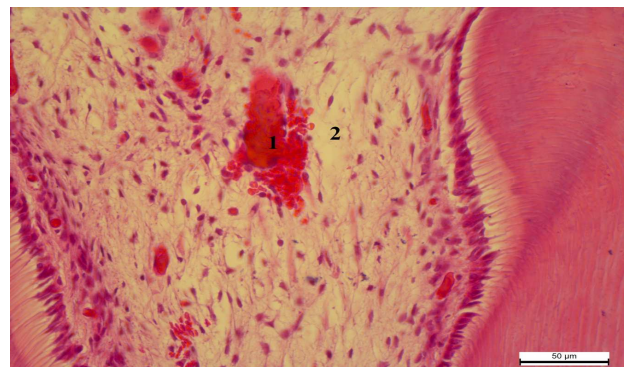


Fig. 2. Coronal pulp lesions in medium dental caries. H&E stain. 400 $\times$  magnification.

1 – hemorrhage in the central region of the pulp; 2 – edema of the main substance of the central region of the pulp; 3 – moderate edema of the supraodontoblastic space.

Histological changes in the pulp in medium caries were manifested by vascular hyperemia and stasis. In some vessels of the central region of the coronary pulp the hyaline, less often erythrocytic thrombi, were formed. In addition, in the central and peripheral region of the pulp diapedetic hemorrhages were visualized.

The main substance of the loose connective tissue of the pulp was swollen, especially in the coronal part. Moreover, in this part sporadic minor cellular infiltrations were visualized, mainly by lymphocytes, plasmacytes and single neutrophils. A significant amount of transsudate was accumulated in the supraodontoblastic space, between individual odontoblastic processes. In the areas of the projection of carious cavity the odontoblasts underwent necrotic lesions, localized in separate groups. The predentin was loosened, the odontoblastic processes were often destroyed (fig. 2).

A moderate vascular hyperemia, a minor mixed-cell inflammatory infiltration with no stasis was observed in the root pulp. Slightly pronounced proliferative odontoblastic processes and an increase in the number of preodontoblasts were detected. The remaining odontoblasts had an oblique or vertical orientation.

In deep caries of the approximal surfaces (without perforation), signs of acute serous pulpitis, accompanied by severe necrotic lesions of the odontoblasts, with disorganization of the peripheral layer of the pulp were revealed in the pulp. Inflammatory hyperemia, stasis, marginal standing of the neutrophilic granulocytes, hyaline, erythrocytic thrombi, extensive hemorrhages, edema of the supraodontoblastic space with the destruction of the odontoblastic processes was found in the vessels. Mainly hyperemia, stasis, isolated erythrocytic or hyaline thrombi, diapedetic hemorrhages were found in the root pulp. The coronal and root pulp stroma was focally infiltrated with lymphocytes, plasma cells, neutrophilic granulocytes, macrophages. In addition, deep carious lesions of the approximal surfaces of molars without perforations of the pulp cavity, inflammation in the pulp and sites, adjacent to the zone of carious destruction of the dentin were more pronounced in comparison with the level of inflammation, which was observed in the deep carious lesions of the occlusive surfaces of the molars (fig. 3).

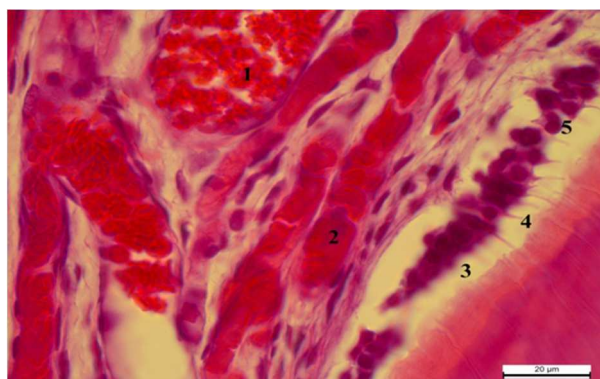


Fig. 3. Root pulp lesions in deep approximal caries. H&E stain. 1000×magnification.

1 – vascular hyperemia; 2 – stasis; 3 – edema of the supraodontoblastic space; 4 – destruction of the odontoblastic processes; 5 – necrobiotic lesions of the odontoblasts.

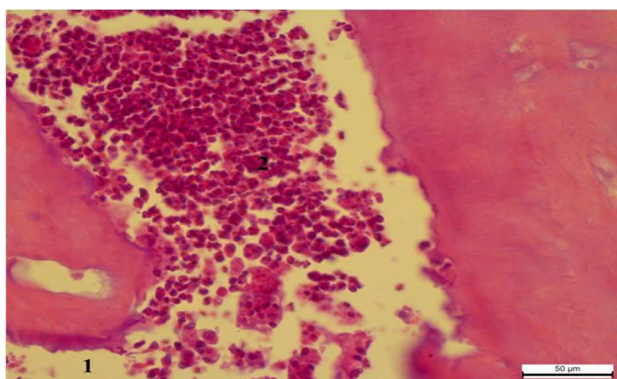


Fig. 4. Pulp lesions in deep dental caries with perforation. H&E stain. 400× magnification.

1 – the zone of dentin destruction; 2 – necrosis and diffuse leukocytic infiltration of the pulp.

On 154-168 days, a deep caries with perforation in the pulp chamber developed, accompanied by the development of purulent inflammation, passing from the coronal part of the pulp to the root part of the pulp and resulted in pulp gangrene (fig. 4).

The findings of the present experimental study are in concordance with the findings of the study [8], which compares the level of inflammatory pulp reaction in occlusal and deep approximal caries in deciduous molars of children.

Currently, pulp-preserving methods of treating deep carious lesions [7] by partial dentin excavation and indirect pulp coverage is tending to increase globally, therefore, it is recommended to take into account the localization of carious lesion, its depth and the state of the dental pulp. The latter criterion can be judged by the findings of our experimental study.

The resulting data on the experimental animals have found that in the deep carious lesions of molars without perforation of the pulp cavity, morphological changes in the pulp of molars were more pronounced in the presence of deep carious lesions of approximal surfaces in comparison with morphological changes observed in the presence of deep caries of chewing surfaces. This indicates the potential occurrence of more frequent complications in the conservative treatment of deep carious lesions of approximal surfaces in comparison with deep lesions of chewing surfaces.

In most studies, the method of indirect coating of dental pulp with sparing preparation of caries-modified dentin (one-stage or two-stage) is considered to be more rational and predictable approach to preserving the vitality of pulp tissues in the long term than the method of radical preparation of carious cavity, in which the opening of a horn of pulp occurs in most cases. Some publications report even about the possibility of almost complete preservation of caries-modified dentin with the isolation of the carious cavity only within the limits of the enamel [5, 11]. However, basically, these studies were conducted with the localization of carious cavities of Blake's Class I, which doubts the success and rationality of using this approach in the localization of deep carious lesions on the approximal surfaces, especially when it comes to deciduous teeth [6].

In this connection, when choosing the method of treatment of deep carious lesions of deciduous teeth, it is necessary to take into account the localization of the carious process and reasonably choose the method of treatment.

### Conclusion

The intensity of dental caries and localization of deep carious lesions are important factors in the prediction of the effectiveness of conservative treatment of deep carious lesions. Dental pulp carious lesion depends not only on the degree of carious process, but also on its localization, which should be taken into account when choosing the optimal method of treatment of dental caries, which also prevents the development of its complications.

### References

1. Grinishin O, Filenko B. Morphological changes of tooth tissues in experimental deep caries in rats. Bulletin of problems biology and medicine. 2014; 2, (107): 119-22. [in Ukrainian]
2. Sheshukova OV, Trufanova VP. Pokaznyky urazhennya kariyosom ta jogo uskladnennyamy v ditej u regioni z vysokym vmistom ftoru v pytnij vodi. Ukrayinskyj stomatologichnyj almanax. 2011; 3: 97-8. [in Ukrainian]
3. Smolyar NI, Solonko GM. Chastota uskladnenogo kariyosu molochnyh zubiv u ditej, yakym provodylas sanaciya pid zagalnym znebolyuvannyam. Visnyk stomatologiyi. 2013; 1: 129-31. [in Ukrainian]
4. Bjorndal L. The caries process and its effect on the pulp: the science is changing and so is our understanding. J Endod. 2008; 34: 52-5.
5. Browning WD, Chan DC, Swift EJ. Critical appraisal: approaches to caries removal: what the clinical evidence says. J. Esthet Restor Dent. 2013; 25 (2): 141-51.
6. Duggal MS, Curzon MEJ, Fayle SA, Toynba KJ, Robertson AJ. Restorative Techniques in Paediatric Dentistry : An Illustrated Guide to the Restoration of Extensive Carious Primary Teeth. 2nd edition. Boca Raton, Florida: CRC Press; 2002. 152 p.
7. Franzon R, Guimaraes LF, Magalhaes CE, Haas AN, Araujo FB. Outcomes of One-Step Incomplete and Complete Excavation in Primary Teeth: A 24-Month Randomized Controlled Trial. Caries Res. 2014; 48: 376-83.
8. Kassa D, Day P, Hjh A, Duggal M. Histological comparison of pulpal inflammation in primary teeth with occlusal or proximal caries. International Journal of Pediatric Dentistry. 2009; 19: 26-33.
9. Oliveira EF, Carminatti G, Fontanella V, Maltz M. The monitoring of deep caries lesions after incomplete dentine caries removal: results after 14–18 months. Clin Oral Investigat. 2006; 10 (2): 134-9.
10. Simon S, Cooper P, Berdal A. Understanding pulp biology for routine clinical practice. ENDO (Engl). 2009; 3: 171-84.
11. Thompson V, Craig RG, Curro FA, Green WS, Ship JA. Treatment of deep carious lesions by complete excavation or partial removal: a critical review. J Am Dent Assoc. 2008; 139: 705-12.
12. Van der Sluis L, Kidd E, Gruythuisen R, Peters L. Preventive endodontics – an argument for avoiding root canal treatment. ENDO (Engl). 2013; 7 (4): 259-74.

### Реферати

#### МОРФО-ЭКСПЕРИМЕНТАЛЬНЕ ДОСЛІДЖЕННЯ ЗМІН ПУЛЬПИ ЗУБА НА РІЗНИХ СТАДІЯХ КАРІЕСУ

Гринишин О.Б., Дидик Н.М., Филенко Б.М.

Чисельні дослідження свідчать, що у структурі ураженості каріосом тимчасових зубів спостерігається високий відсоток ускладненого карієсу. Метою дослідження було вивчення морфологічних змін пульпи зуба при експериментальному карієсі різної стадії у шурів з теоретичним обґрунтуванням принципів лікування пульпіту. Дослідження виконані на 50 білих беспородних щурах-самцях у яких викликали експериментальний карієс спеціальною карієсогенною дієтою. Спочатку визначали глибину каріозного ураження емалі та дентину на видалених недекальцинованих щелепах з подальшим виготовленням гістологічних препаратів на яких вивчали морфологічні зміни пульпи. Виявлено потенційну можливість виникнення більш частих ускладнень при глибоких каріозних ураженнях апроксимальних поверхонь у порівнянні із глибокими

#### МОРФО-ЭКСПЕРИМЕНТАЛЬНОЕ ИССЛЕДОВАНИЕ ИЗМЕНЕНИЙ ПУЛЬПЫ ЗУБА НА РАЗНЫХ СТАДИЯХ КАРИЕСА

Гринишин О.Б., Дыдык Н.М., Филенко Б.М.

Многочисленные исследования показывают, что в структуре пораженности карисом временных зубов наблюдается высокий процент осложненного кариса. Целью исследования было изучение морфологических изменений пульпы зуба при экспериментальном карисе различной стадии у крыс с теоретическим обоснованием принципов лечения пульпита. Исследования выполнены на 50 белых беспородных крысах-самцах в которых вызвали экспериментальный карис специальной карисогенной диетой. Сначала определяли глубину каріозного поражения эмали и дентина на удаленных недекальцинованных челюстях с последующим изготовлением гистологических препаратов на которых изучались морфологические изменения пульпы. Вывявлено потенциальную возможность возникновения более частых осложнений при глубоких каріозных поражениях апроксимальных поверхностей по сравнению с

ураженнями жувальних поверхонь зубів. Отже, ураження пульпи зуба при карієсі залежить не лише від ступеня каріозного процесу, але й від його локалізації, що потрібно враховувати при виборі оптимального методу лікування карієсу, що також попередить розвиток його ускладнень.

**Ключові слова:** експериментальний карієс, пульпа, морфологія.

Стаття надійшла 15.05.2019 р.

глибокими поразками жевательных поверхностей зубов. Итак, поражения пульпы зуба при кариесе зависит не только от степени кариозного процесса, но и от его локализации, что нужно учитывать при выборе оптимального метода лечения кариеса, также предупредит развитие его осложнений.

**Ключевые слова:** экспериментальный кариес, пульпа, морфология.

Рецензент Єрошенко Г.А.

DOI 10.26724/2079-8334-2020-1-71-180-183

UDC 616-092:[616.314.17:616-008.9]-599.323.4

A.M. Yelinska, S.V. Denisenko, L.I. Liashenko, V.O. Kostenko  
Ukrainian Medical Stomatological Academy, Poltava

## INFLUENCE OF INHIBITORS OF TRANSCRIPTION FACTOR KAPPA B ON DEPOLYMERIZATION OF BIOPOLYMERS IN PERIODONTAL CONNECTIVE TISSUE UNDER SYSTEMIC INFLAMMATORY RESPONSE IN RATS

e-mail: kostenko11111@rambler.ru

The article presents the results obtained in the experiment on 40 white rats aimed at investigating the influence of ammonium pyrrolidine dithiocarbamate (APDTC), an inhibitor of the nuclear translocation of the transcription factor  $\kappa$ B (NF- $\kappa$ B), on the depolymerization of collagen, proteoglycans and sialoglycoproteins in extracellular matrix of soft and osseous tissues under modeled systemic inflammatory response (SIR). The latter was induced by intraperitoneal administration of lipopolysaccharide *Salmonella typhi* (pyrogenalum) in a dose of 0.4  $\mu$ g/kg of weight 3 times during the first week, and once a week for the following 7 weeks. It has been shown the SIR simulation is accompanied by activation of the collagenolysis as well as depolymerization of proteoglycans and sialoglycoproteins in the tissues of the gum, periodontal ligament and alveolar process of the jaws as evidenced by a considerable increase in the concentration of free hydroxyproline, glycosaminoglycans and N-acetylneuraminic acid. The application of APDTC during SIR significantly reduces the depolymerization of collagen, proteoglycans and sialoglycoproteins in soft and bone periodontal tissues, and limits the degree of resorption of the jaw alveolar process. This allows us to conclude the use of this compound during SIR is an effective means to correct disruption the periodontal connective tissue in rats.

**Key words:** nuclear factor kappa B, systemic inflammatory response, connective tissue biopolymers, collagen, proteoglycans, glycoproteins, periodontium.

*The work is a part of the research project "The role of reactive oxygen species, nitric oxide system and transcriptional factors in the mechanisms of pathological systemogenesis", state registration No. 0114U004941.*

Depolymerization of periodontal connective tissue biopolymers is considered to be an important link in the pathogenesis of chronic periodontitis under the influence of general (emotional and pain stress) [14] and local factors [10] that impedes its treatment by means of regenerative therapy [5]. Previously, we have shown that the modeling of lipopolysaccharide (LPS)-induced systemic inflammatory response (SIR) in periodontal tissues is accompanied by an increase in production of reactive oxygen and nitrogen species by mitochondria, endoplasmic reticulum and NO synthase (NOS), as well as NADPH-oxidase of white blood cells. The progression of oxidative-nitrosative stress results in the collagenolysis and the depolymerization of proteoglycans and sialoglycoproteins, both in the connective tissue of the gums and the periodontal ligament and in the bone tissue of the alveolar process [1]. It is noteworthy that most of the activators of NF- $\kappa$ B as bacterial LPS, proinflammatory cytokines, E2 prostaglandins, stress, viruses, etc. are involved in the pathogenesis of chronic periodontitis [3].

However, the relevant literature presents contradictory information regarding the effect of NF- $\kappa$ B on connective tissue status during inflammation [2, 6]. Solving this problem is of exceptional importance in searching new approaches towards the pathogenetic therapy of inflammatory and dystrophic periodontal diseases.

**The purpose** of the study was to investigate the effect of ammonium pyrrolidine dithiocarbamate (APDTC), an inhibitor of the nuclear translocation of the transcription factor  $\kappa$ B (NF- $\kappa$ B), on the depolymerization of collagen, proteoglycans and sialoglycoproteins in extracellular matrix of soft and osseous tissues in periodontium of rats under modeled systemic inflammatory response induced with LPS *Salmonella typhi*.

**Materials and methods.** The series of the experiment were performed on 30 white male Wistar rats weighing 180-220 g, which were divided into 3 groups (with 10 animals in each group): the 1st group included intact animals, the 2nd group included rats, which were subjected to the systemic administration of LPS (pyrogen, Medgamal, Russia), and the 3rd group consisted of the animals, which received APDTC (manufactured by Sigma-Aldrich, Inc., USA) intraperitoneally in a dose of 76 mg/kg 3 times a week,