

14. Kozar VV, Yeromenko RF, Dolzhykova OV, Horbenko NI, Kudria MYa, Yaremenko FH. Zmina kontsentratsii leptynu v ovariektomovanykh shchuriv iz metabolichnym syndromom za umov vvedennia spoluk z imunomoduliuuichoio aktyvnistiu. Ukrainskyi zhurnal medytsyny, biolohiyi ta sportu. 2018;3(1(10)):40–3. doi: 10.26693/JMBS03.01.040.

15. Martijn JL Verhulst, Bruno G Loos, Victor EA Gerdes, Wijnand J Teeuv. Evaluating all potential oral complications of diabetes mellitus. Front. Endocrinology. 2019;1:154–67. doi: 10.3389/fendo.2019.00056.

Стаття надійшла 24.06.2020 р.

DOI 10.26724/2079-8334-2021-3-77-214-219

UDC 612.127.2:616.314–002.4+616.314.17–008.1(612.015.6)

V.S. Ivanov, Ye.K. Tkachenko, O.V. Djenha, S.A. Schnayder, T.O. Pyndus  
State Establishment "The Institute of Stomatology and Maxillo-Facial Surgery National Academy  
of Medical Sciences of Ukraine", Odessa. <sup>1</sup>Lviv Medical Institute, Lviv

### CORRECTION BY THE PREPARATION OF PLANT POLYPHENOLS OF METABOLIC CHANGES OF TISSUES OF RATS ORAL CAVITY UNDER CONDITIONS OF INTRAUTERINE HYPOXIA AND CARIOGENIC DIET

e-mail: ivanov-dent@ukr.net

The work is devoted to the study of the effect of the preparation of plant polyphenols on the dental status and the state of the tissues of the oral cavity of rats under conditions of intrauterine hypoxia and cariogenic diet. The experiment was carried out on 36 white rats of both sexes: 30 females and 6 males. A preparation of plant polyphenols had a caries-preventive and parodontoprotective effect in the offspring of rats under conditions of intrauterine hypoxia and a cariogenic diet. In the oral mucosa, the preparation showed anti-inflammatory and antioxidant effects. The preparation improved state of collagen in the intercellular matrix of the connective tissue of rat parodontal tissue as a result of normalization of the levels of general and free oxyproline in the oral mucosa, as well as general oxyproline in the alveolar bone of rats.

**Key words:** hypoxia, caries-prophylactic effect, metabolic markers, plant polyphenols, rats.

В.С. Іванов, Є.К. Ткаченко, О.В. Дєньга, С.А. Шнайдер, Т.О. Пиндус

### КОРЕКЦІЯ ПРЕПАРАТОМ РОСЛИННИХ ПОЛІФЕНОЛІВ МЕТАБОЛІЧНИХ ЗМІН ТКАНИН РОТОВОЇ ПОРОЖНИНИ ЩУРІВ В УМОВАХ ДІЇ ВНУТРІШНЬОУТРОБНОЇ ГІПОКСІЇ ТА КАРІСОГЕННОГО РАЦІОНУ

Робота присвячена вивченню впливу препарату рослинних поліфенолів на стоматологічний статус і стан тканин ротової порожнини щурів в умовах дії внутрішньоутробної гіпоксії та карієсогенного раціону. Дослід проведено на 36 білих щурах обох статей: 30 самок і 6 самців. Препарат рослинних поліфенолів в умовах дії внутрішньоутробної гіпоксії і карієсогенний раціон у потомства цих щурів мав карієспрофілактичну і пародонтопротекторну дію. У слизовій оболонці порожнини рота препарат проявив протизапальну і антиоксидантну дію. Під дією препарату поліпшувався стан колагену міжклітинного матриксу сполучної тканини пародонту щурів в результаті нормалізації рівнів загального та вільного оксипроліну в слизовій оболонці порожнини рота, а також загального оксипроліну в кістці альвеолярного відростка щурів.

**Ключові слова:** гіпоксія, карієс-профілактична дія, метаболічні маркери, рослинні поліфеноли, щури.

*The work is a fragment of the research project "Influence of hypoxia on the processes of collagen formation and mineralization on models of dental pathology and correction of the obtained disorders", state registration No. 0118U006963.*

Hypoxia is a typical pathological process that occurs when there is insufficient oxygen supply to tissues or when its utilization is impaired. There are several types of hypoxic conditions, among which tissue or histotoxic hypoxia has been studied. This type of hypoxia develops as a result of a violation of the ability of cells to absorb oxygen (with its normal delivery to cells) or in conditions of a decrease in the effectiveness of biological oxidation as a result of the uncoupling of oxidation and phosphorylation processes.

Utilization of oxygen by tissues can be hampered by the action of various inhibitors of biological oxidation enzymes, changes in the physicochemical conditions of their action, disruption of the synthesis of tissue respiration enzymes.

One of the most important pathogenetic factors in the development of tissue hypoxia is the disintegration of the structure of mitochondrial membranes, which occurs under the influence of various etiological factors – bacterial, hormonal imbalance, during aging of the body [12].

Fetal hypoxia is a complex of changes in the fetus' body due to insufficient oxygen supply, which leads to fetal growth retardation, the appearance of developmental abnormalities. In children who have undergone hypoxia in the antenatal period, the incidence of developmental delays is significantly increased, and an increase in the incidence of caries is shown in comparison with healthy children. [3]. They develop

hypoxic syndrome with impaired redox processes in mitochondria, activation of the glycolysis process, which is accompanied by an increase in lactic and pyruvic acids, peroxide compounds in the tissues [1].

In connection with the above, the use of antihypoxants and antioxidants in clinical practice is important for the prevention and treatment of such conditions.

Experimental data from biochemical and cytomorphological studies of recent years indicate a significant role of plant polyphenols (PPP) in ensuring the resistance of the epithelial tissue of the oral cavity to damaging factors of different nature [9]. Anti-inflammatory properties and an increase in the rate of epithelization and regeneration of rat gingival tissues under the influence of plant polyphenols were established [9].

Plants-antihypoxants and antioxidants include plantain (*Plantago major*), the leaves of which contain a wide variety of flavonoids, bitter and tannins, enzymes (emulgin, invertin), vitamin C, citric acid, carotene, mucus, phytoncides, saponins, aucubin, fatty oils, etc.

Preparations from plantain leaves have a multifaceted healing effect: wound healing, anti-inflammatory, hemostatic, analgesic, bactericidal, anti-allergic.

**The purpose** of the work was to study the effect of the preparation of plant polyphenols from the leaves of *Plantago major* on the dental status and the state of the tissues of the oral cavity of rats under conditions of intrauterine hypoxia and cariogenic diet.

**Materials and methods.** The experiment involved 36 white Wistar rats of herd breeding of both sexes: 30 females and 6 males, which were kept on a standard vivarium diet.

In mature rats (9 females), 2 males were added to reproduce the offspring. Then, in these females, presumably from 10 to 19 days of pregnancy, hypoxia (H) of uncoupling of oxidation and phosphorylation processes was reproduced [9] by intraperitoneal administration during pregnancy of "Warfarin Nycomed". (Takeda Pharma, Poland) at a dose of 1.5 mg/kg body weight of rats. After birth, rat pups at 1 month of age were put on a cariogenic diet (CgD) [4]. The intact group consisted of 6 rats. During 30 days, rats on the background of hypoxia and CgD received per os Preparation of polyphenols of leaves of *Plantago major* (ZAT "Liktravi", Zhitomir, Ukraine). Working name PPP, obtained by original laboratory technology [15], the amount of polyphenols in PPP preparation is 7.83 mg/g of raw material.

The animals were removed from the experiment by total bloodletting from the heart performed under general anesthesia (sodium thiopental 40 mg/kg). Having previously separated the oral mucosa, the jaws were dissected out. The objects of biochemical studies were the liver, the supernatant of the homogenates of the oral mucosa (25 mg/ml), the bones of the alveolar ridge (50 mg/ml), and the pulp of the incisors of rats. The supernatant was obtained by centrifugation in a RS – 6 centrifuge for 15 minutes at 3000 rpm at a temperature of +4° C.

The state of the intercellular matrix (ICM) of the connective tissue (CT) was assessed by the state of the level of collagen (according to the content of bound, free and total hydroxyproline [6]) and glycosaminoglycans (GAG) in parodontal tissues [11]. The level of lipid peroxidation (LPO) products was assessed by the content of malondialdehyde (MDH) in tissues by the thiobarbituric method [5]. The state of the physiological antioxidant system (PAS) was assessed by the activity of glutathione peroxidase (GPO) [11] and catalase [10].

To assess the state of rat tissues, biochemical parameters were determined by unified methods using commercial reagent kits: alkaline phosphatase (ALP) activity, acid phosphatase (AP) activity, calcium, phosphorus content, lactate dehydrogenase (LDH) activity, pyruvate content (produced by UV – Abris+).

The number of carious cavities (per 1 rat), as well as the depth of caries lesions of the rats' teeth (in points) were determined on macro-preparations of the isolated rat jaws. The isolated jaws of rats were subjected to morphometric examination. [8].

The results were processed by variational statistical methods of analysis using the Microsoft Office Excel 2016 software. Statistical processing of the experimental study results was carried out by the methods of variation analysis using the Student's test. The difference was considered statistically significant at  $p < 0.01$ .

**Results of the study and their discussion.** The study of the effect of the PPP preparation was carried out under conditions of the combined action of intrauterine hypoxia, the uncoupling of oxidation and phosphorylation processes and a cariogenic diet.

The conducted studies revealed a significant decrease in resorptive processes in the bone tissue of the parodontium – the resorption of the parodontal bone under the influence of the PPP drug decreased by 8 % ( $p = 0.05$ ; 100 % in the control group; table 1).

Under the influence of the preparation, the number of carious cavities decreased by 30 % ( $p_1 = 0.04$ ) compared to the control group (100 %). The depth of dental caries lesions also decreased significantly by 31.4 % ( $p_1 = 0.04$ ) (in points).

Table 1

**The effect of PPP on the condition of the dentition in rats under conditions of hypoxia and cariogenic diet reproduction, M±m**

Indices	Indices of bone resorption of parodontal tissue (%)	Number of carious lesions per 1 rat	Depth of dental caries lesions (in points)
Intact	17.2±0.7	1.9±0.4	1.9±0.4
H+CgD	17.2±0.5	3.4±0.3 p=0.03	3.5±0.2 p=0.016
H+CgD+PPP	15.8±0.4 p <sub>1</sub> =0.05	2.4±0.3 p <sub>1</sub> =0.04	2.4±0.4 p <sub>1</sub> =0.04

Note. p – the index of the reliability of differences relative to the intact group; p<sub>1</sub> – the index of the reliability of differences relative to the control group;

Changes in the activity of acid and alkaline phosphatases in the pulp of rat teeth indicate the metabolism of odontoclasts and odontoblasts in this study object. AP activity (index of odontoclast metabolism) decreased by 18 % (p>0.05) and did not differ significantly from the data of the intact group (table 2).

Table 2

**Effect of PPP preparation on biochemical parameters in dental pulp and parodontal tissues of rats, M ± m**

Indexes	Animal groups		
	Intact	H+CgD	H+CgD+PPP
	Dental pulp		
AP (nkat/l)	31.0±5.61	51.7±5.00 p=0.03	42.6±3.41
ALP (mkat/l)	1.98±0.16	1.32±0.29 p=0.08	1.01±0.070 p=0.003 p <sub>1</sub> =0.002
	Oral mucosa		
AL (nkat/g)	89.8±5.10	265±10.6 p<0.001	119±7.40 p=0.015 p <sub>1</sub> <0.001
	Alveolar bone		
AL (nkat/g)	61.8±2.00	155±0.025 p<0.001	82.2±137 p<0.001 p <sub>1</sub> <0.001
ALP (mkat/g)	193±2.20	73.5±1.03 p<0.001	126±1.73 p<0.001 p <sub>1</sub> <0.001
Calcium (mmol/g)	7.30±0.12	2.68±0.090 p<0.001	6.95±0.27 p <sub>1</sub> <0.001
Phosphorus (mmol/g)	8.07±0.25	4.18±0.080 p<0.001	7.21±0.12 p <sub>1</sub> <0.001

Note. p – index of the reliability of differences relative to the intact group; p<sub>1</sub> – the index of the reliability of differences relative to the control group;

The alkaline phosphatase activity in the dental pulp decreased by 24 % (p<sub>1</sub>=0.002) compared with the G+CgD group and by 51 % (p=0.003) compared with the intact one, which indicates insufficient functioning of odontoblasts in this study object under the influence of the preparation.

PPP had a significant effect on the state of mineral metabolism in the alveolar bone under the action of intrauterine hypoxia and cariogenic diet. Thus, the preparation increased the alkaline phosphatase activity by 1.7 times compared to the control (p<sub>1</sub><0.001), but was slightly lower than in the intact group.

The content of calcium and phosphorus increased 2.6 and 1.7 times, respectively, and approached the data of intact groups.

In the bone of the alveolar bone, the activity of acid phosphatase, as an indicator of the activity of osteoclasts, decreased 1.9 times (p<sub>1</sub>=0.001) and correlated with a decrease in the parameters of osteoresorption of the parodontal bone tissue (table 1).

The activity of acid phosphatase under the influence of PPP preparation changed in soft and hard parodontal tissues of rats. Thus, the activity of the pro-inflammatory enzyme AP in the oral mucosa decreased 2.2 times (p<sub>1</sub><0.001), which indicated the anti-inflammatory properties of the preparation.

Indirectly, the decrease in inflammation in the alveolar bone was evidenced by a 30 % decrease (p<sub>1</sub>=0.001) in the MDH content under the action of PPP and practically corresponded to the data of the intact group. In the oral mucosa of rats under the action of the drug, the MDH content decreased by 14 % (p>0.05) compared to the control (H+CgD) and did not differ from the data of the intact group.

In the liver, PPP preparation normalized the activity of antioxidant enzymes – catalase and glutathione peroxidase. In the oral mucosa and the alveolar bone, the activity of glutathione peroxidase was consistent with the data of intact groups.

Catalase activity in the oral mucosa increased by 54 % under the influence of PPP ( $p_1=0.05$ ). In the parodontal bone tissue, catalase activity did not change significantly.

Under the action of the PPP preparation, the pyruvate content decreased in all the studied objects – in the liver and parodontal tissues as compared with the data of the control groups. Thus, the content of pyruvate in the liver decreased by 3 times ( $p_1<0.001$ ), by 1.6 times in the oral mucosa and in the alveolar bone ( $p_1=0.001$ ;  $p_1=0.007$ , respectively; fig. 1). The levels of pyruvate in the liver and parodontal tissues were consistent with those of the intact groups.

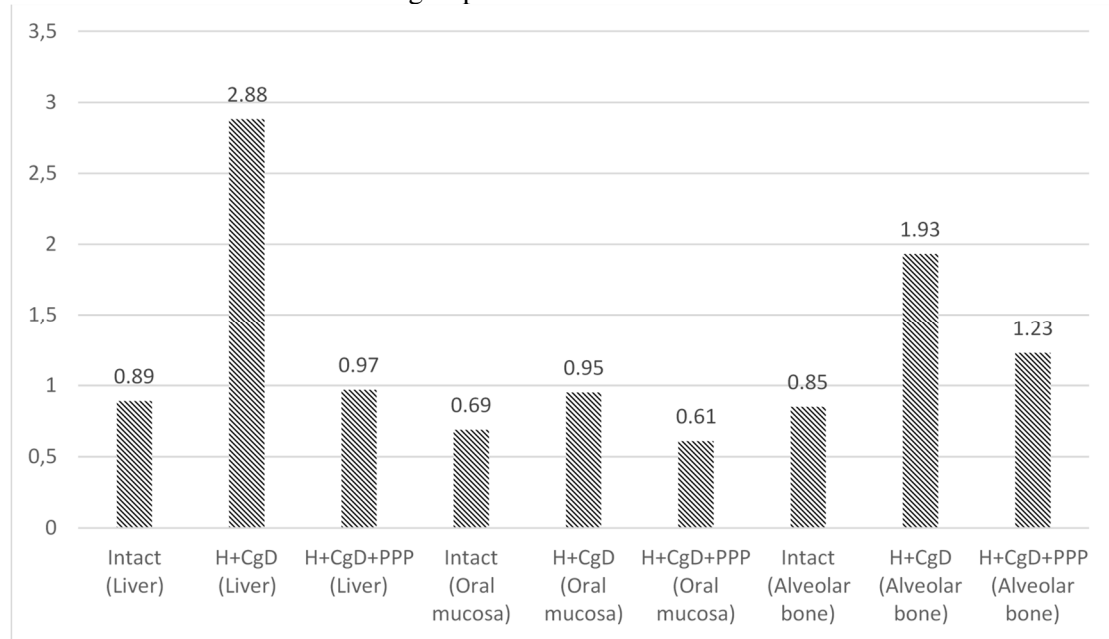


Fig. 1. Effect of PPP preparation on pyruvate content in rat tissues, mmol/g

Under the influence of the preparation, the LDH activity in the liver decreased by 1.5 times ( $p_1=0.001$ ) compared to the control group.

In the parodontal tissues, LDH activity increased: by 2 times ( $p_1<0.001$ ) in the oral mucosa and by 2.6 times ( $p_1<0.001$ ) in the alveolar bone, which may indicate a decrease in lactate levels under the influence of PPP in these research objects. LDH activity in parodontal tissues corresponded to values in intact groups (fig. 2).

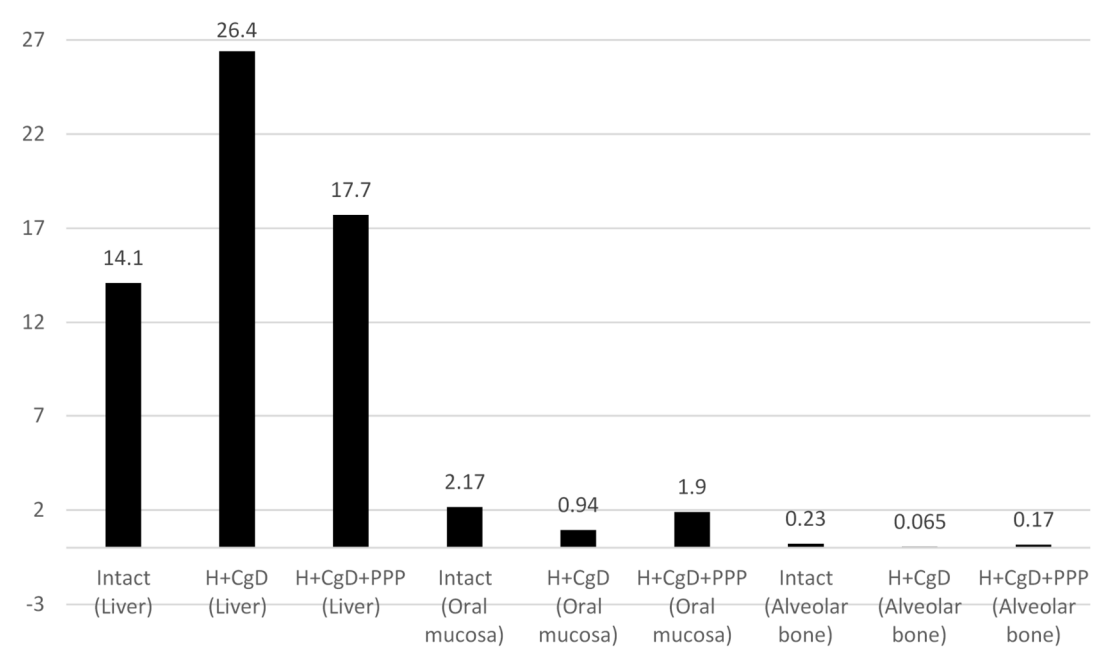


Fig. 2. Effect of PPP preparation on LDH activity in rat tissues, µkat/g

The parameters of the ICM state of the parodontium in rats are presented in figure 3 and 4. Thus, the PPP preparation increased the content of total oxyproline in the oral mucosa and alveolar bone in comparison with the data of the control groups (H+CgD) and normalized relative to intact values.

The PPP preparation significantly increased the levels of bound oxyproline in the oral mucosa by 1.8 times ( $p_1 < 0.001$ ) and 3.6 times ( $p_1 < 0.001$ ) in the parodontal bone tissue compared to the control groups. In the bone of the alveolar bone, the content of bound oxyproline was 3 times ( $p_1 < 0.001$ ) higher than the data in the intact group (Fig 3).

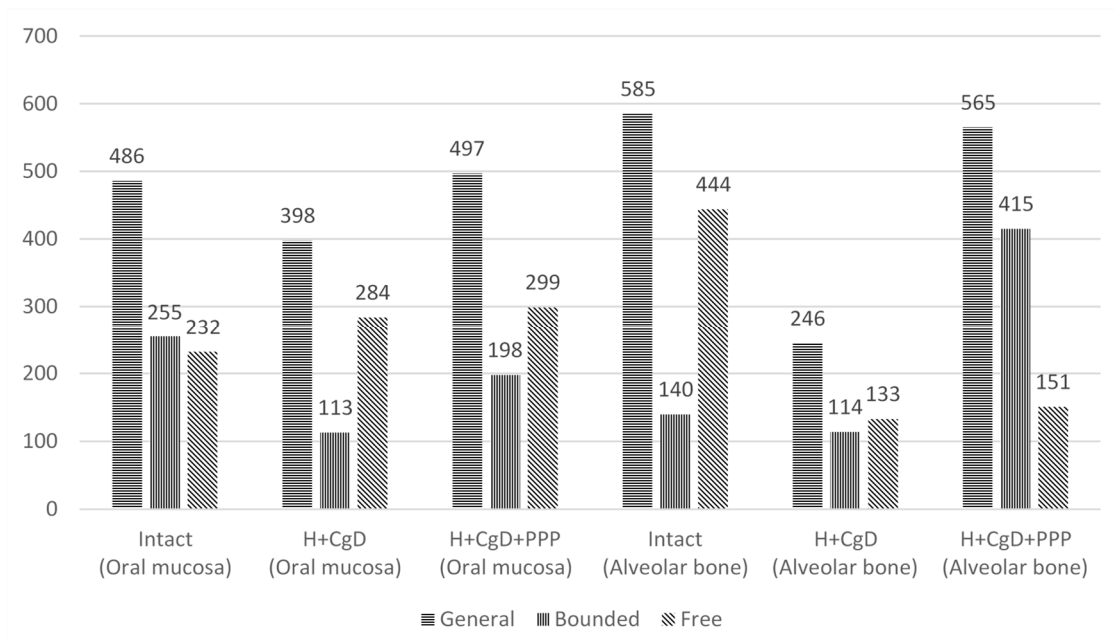


Fig. 3. Influence of PPP preparation on content of oxyproline, µmol/g

The content of the gel-forming environment ICM, represented by GAG, increased in the oral mucosa by 1.5 times ( $p_1 = 0.011$ ) and more significantly by 5.7 times ( $p_1 < 0.001$ ) in the alveolar bone. At the same time, these indicators did not reach the levels of intact groups (Fig 4).

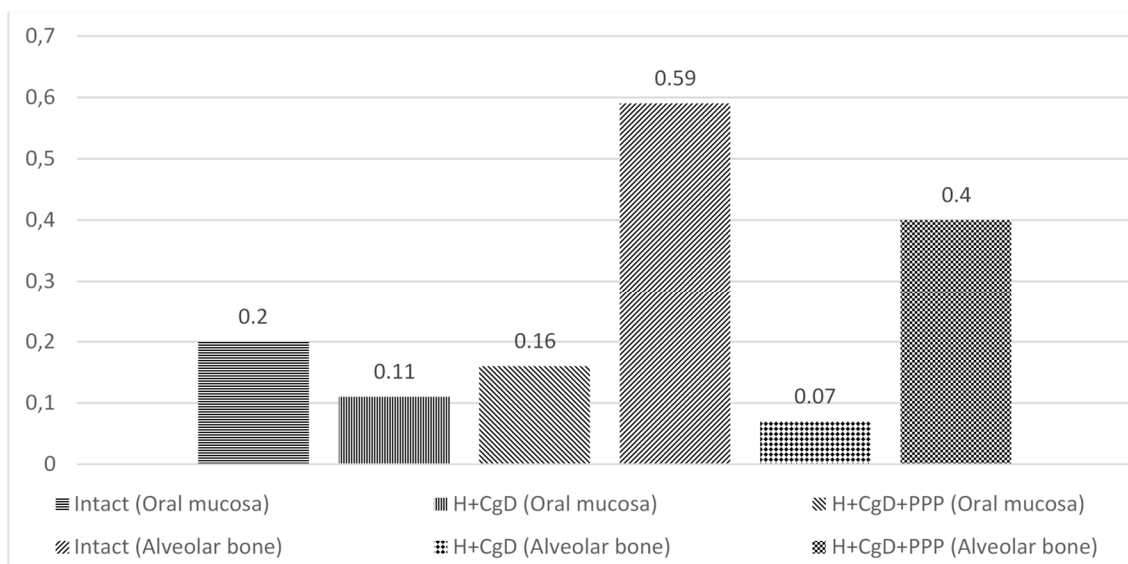


Fig. 4. Influence of PPP preparation on content of glycosaminoglycans, mg/g

The problem of prenatal hypoxia and its long-term consequences has been extremely urgent for many decades and attracts the attention of scientists, doctors of various specialties in terms of explaining the mechanisms of development and possible prevention of various pathological conditions [2, 13, 14]. However, in our opinion, the existing studies devoted to the treatment of disorders in the oral cavity of children who underwent hypoxia in the antenatal period are rather few [7, 12], therefore, the obtained results will allow to develop in the future an effective therapeutic and prophylactic complex for the correction of metabolic changes in the oral cavity in such patients. As a result of the research carried out, the following should be stated. The preparation of plantain leaves polyphenols (PPP preparation) under

conditions of intrauterine tissue hypoxia and cariogenic diet in the offspring of these rats had a caries-prophylactic effect. It reduced the number of dental caries lesions and reduced the aggressiveness of the carious process. Parodontal bone resorption rates also decreased, correlating with a significant decrease in this object of study in the activity of AP as a marker enzyme of the action of osteoclasts. The preparation improved mineral metabolism in the alveolar bone. In the oral mucosa of rats, the preparation showed an anti-inflammatory effect – it reduced the activity of the pro-inflammatory enzyme, acid phosphatase. The antioxidant effect of the preparation was expressed in a decrease in the level of LPO processes, as well as in the normalization of the activity of FAS enzymes – catalase and glutathione peroxidase. PPP improved the state of collagen in the intercellular matrix of the connective tissue of rat parodontal tissue as a result of normalization of the levels of general and free oxyproline in the oral mucosa, as well as general oxyproline in the alveolar bone of rats. In these study objects, the levels of bound oxyproline exceeded the values in the intact groups.

### Conclusions

1. The preparation of *Plantago major* leaf polyphenols under conditions of intrauterine tissue hypoxia and cariogenic diet in the offspring of these rats had a caries- prophylactic effect.
2. In the oral mucosa of rats, the preparation showed an anti-inflammatory effect – it reduced the activity of the pro-inflammatory enzyme – acid phosphatase.
3. Almost complete normalization of the levels of metabolic markers of hypoxia in the parodontal tissues of rats under the influence of PPP was revealed.

### References

1. Gridin LA. Sovremennyye predstavleniya o fiziologicheskikh i lechebno–profilakticheskikh effektakh deystviya gipoksii i giperkapnii. *Medsitsina*. 2016; 4(3):45–68. [in Russian]
2. Zarubina IV. Sovremennyye predstavleniya o patogeneze gipoksii i ee farmakologicheskoy korrektsii. *Obzory po klinicheskoy farmakologii i lekarstvennoy terapii*. 2011; 9(3):31–48. [in Russian]
3. Kolesova OV. Vzaimosvyaz osobennostey antenatalnogo perioda i pervogo goda zhizni rebenka so srokami prorezyvaniya vremennykh zubov. *Dental Forum. – Obshchestvo s ogranichennoy otvetstvennostyu “Forum stomatologii”*. 2014; 4:50–51. [in Russian]
4. Maksimov AL, Averjanova IV. Informativnost proby s rerespiratsiey dlya otsenki ustoychivosti organizma junoshey k sochetannomu deystviyu gipoksii i giperkapnii. *Rossiyskiy fiziologicheskii zhurnal im. I.M. Sechenova*. 2017; 103(9):1057–1068. [in Russian]
5. Mikhailichenko VY. Patofiziologicheskie aspekty gipotireoza u krysv v eksperimente. *Vestnik neotlozhnoy i vosstanovitelnoy meditsiny*. 2012; 13(1):86–89. [in Russian]
6. Nikolaeva AV. Vliyanie preparata polifenolov travy Khvoshcha polevogo na strukturno–funktsionalnoe sostoyanie mezhkletchnogo matriksa parodonta krysv v usloviyakh modelirovaniya parodontita. *Innovatsii v stomatologii*. 2015; 1(7):6–10 [in Russian]
7. Pisareva EV, Vlasov MJ, Golub YV, Stadler EP. Modifikatsiya metoda opredeleniya fraktsiy oksiprolina v syvorotke krovi. *Vestnik Samarskogo gosudarstvennogo universiteta*. 2012; 9:211–216. [in Russian]
8. Plotnikova SY, Shastin YN, Zimina YI, Koretskaya EA. Antenatalnaya profilaktika kariesa. *Sovremennyye tendentsii razvitiya nauki i tehnologii*. 2016; 5–1:134–135. [in Russian]
9. Sukhova TV, Zelenina TG. Izmeneniya nervnoy sistemy i ikh znachenie v patogeneze generalizovannogo parodontita. *Klinicheskaya nevrologiya*. 2017; 4:36–41. [in Russian]
10. Tkachenko YeK, Nikolaeva AV, Novoselskaya NG. Vliyanie preparatov rastitelnykh polifenolov i vitaminno–mineralnogo kompleksa na sostoyanie mezhkletchnogo matriksa parodonta i slizistoy obolochki polosti rta krysv pri gipoestrogenii. *Stomatological Bulletin*. 2014; 1(86):16–20. [in Russian]
11. Tsvyakh OO. Vplyv stresu na stan prooksidantno–antioksidantnoy systemy shlunku shhuriv pry nestachi ta nadlyshku melatoninu. *Visnyk problem biolohiyi i medytsyny*. 2013; 3:254–258. [in Ukrainian]
12. Yelinskaya AM, Kostenko VO. Mehanizmy dezorganizatsiyi spoluchnoy tkanyny parodonta shhuriv za umov systemnoho zapalennya. *Aktualni problemi suchasnoy medytsyny: Visnyk ukrayinskoy medychnoy stomatolohichnoy akademii*. 2018; 1(61):175–177. [in Ukrainian]
13. Drogomiretskaya MS, Salama ASK. The morphological and morphometric study of tissues of dentoalveolar system in children with impaired course of the antenatal period. *Medical perspectives*. 2016; 21(1):96–103.
14. Nalivaeva NN, Turner AJ, Zhuravin IA. Role of prenatal hypoxia in brain development, cognitive functions, and neurodegeneration. *Frontiers in neuroscience*. 2018; 12:825.
15. Silverman HS, Wei SK., Haigney MC, Ocampo CJ, Stern MD. Myocyte adaptation to chronic hypoxia and development of tolerance to subsequent acute severe hypoxia. *Circ. Res.* 1997; 5:699–707

Стаття надійшла 28.08.2020 р.