

R.P. Tkachenko, N.Yu. Kondratyuk, O.G. Kuryk^{1,2}, O.M. Mostiuk², L.A. Cherkasova¹,
K.V. Bazdyrev¹, O.L. Kisilenko¹

SSI "Scientific and Practical Center of Preventive and Clinical Medicine",

State Administration of Affairs, Kyiv; ¹Bogomolets National Medical University, Kyiv

²National Taras Shevchenko University of Kyiv, Kyiv

SURGICAL INTERVENTION EFFICACY IN METASTATIC SOFT TISSUE CALCIFICATION AND CALCIPHYLAXIS IN PATIENTS WITH CHRONIC KIDNEY DISEASE

e-mail: rimmatkachenko@i.ua

Secondary hyperparathyroidism develops in patients with chronic kidney disease due to stimulation of the thyroid gland with the emergence of autonomy of their function, which causes metastatic calcification and calciphylaxis. If conservative treatment of this pathology is ineffective, subtotal parathyroidectomy is performed. The purpose of the study was to compare the results of surgical and conservative treatment of patients with secondary hyperparathyroidism with calcification and calciphylaxis. Patients with medical treatment had complaints of pain in the bones and joints, itchy skin, convulsions, while in patients after surgery the symptoms had a clear tendency to decrease. There was the healing of trophic ulcers of the skin, a decrease in the size of calcifications in 2–3 months and their disappearance in a year after parathyroidectomy. Parathyroid hormone levels dropped to normal within a few days after surgery, and calcium and phosphorus levels dropped to safe levels. Therefore, surgery is an effective treatment for patients with chronic kidney disease, as it quickly normalizes laboratory parameters, eliminates clinical manifestations, reduces the manifestations of metastatic soft tissue calcification and intravascular deposition of calcium salts.

Key words: secondary hyperparathyroidism, metastatic calcification, calciphylaxis, chronic kidney disease, subtotal parathyroidectomy

Р.П. Ткаченко, Н.Ю. Кондратюк, О.Г. Курик, О.М. Мостюк, Л.А. Черкасова,
К.В. Баздирєв, О.Л. Кісіленко

ЕФЕКТИВНІСТЬ ОПЕРАТИВНОГО ВТРУЧАННЯ ПРИ МЕТАСТАТИЧНІЙ КАЛЬЦИФІКАЦІЇ М'ЯКИХ ТКАНИН І КАЛЬЦИФІЛАКСІЇ У ПАЦІЄНТІВ З ХРОНІЧНОЮ ХВОРОБОЮ НИРОК

У пацієнтів з хронічною хворобою нирок розвивається вторинний гіперпаратиреоз за рахунок стимуляції прищитоподібних залоз з виникненням автономізації їх функції, що спричиняє метастатичну кальцифікацію і кальцифілаксію. За неефективності консервативного лікування даної патології проводиться субтотальна паратиреоїдектомія. Метою дослідження стало порівняння результатів оперативного і консервативного лікування пацієнтів з вторинним гіперпаратиреозом з кальцифікацією і кальцифілаксією. У пацієнтів з медикаментозним лікуванням зберігалися скарги на біль у кістках і суглобах, свербіж шкіри, судоми, тоді як у пацієнтів після оперативного лікування симптоми мали виразну тенденцію до зниження. Відмічалось загоєння трофічних виразок шкіри, зменшення розмірів кальцифікатів через 2–3 місяці і зникнення їх через рік після паратиреоїдектомії. Рівень паратгормону за кілька діб після операції знижувався до норми, показники кальцію та фосфору – до безпечного рівня. Отже, оперативне втручання є ефективним методом лікування у пацієнтів з хронічною хворобою нирок, оскільки швидко нормалізує лабораторні показники, усуває клінічні прояви, зменшує прояви метастатичної кальцифікації м'яких тканин та внутрішньосудинне відкладання солей кальцію.

Ключові слова: вторинний гіперпаратиреоз, метастатична кальцифікація, кальцифілаксія, хронічна хвороба нирок, субтотальна паратиреоїдектомія.

The study is a fragment of the research project "Optimization of surgical treatment of patients according to the multimodal program of rapid recovery based on the improvement of minimally invasive surgical interventions, in particular with the use of nanobiosensory technologies and their anaesthesia", state registration No. 0119U001046.

Secondary hyperparathyroidism (SHPT) is a disease with a complex pathogenetic mechanism, caused by increased secretion of parathyroid hormone (PTH) with its subsequent effect on phosphorus and calcium metabolism and leading to hyperplasia of the 4 parathyroid glands. Severity of SHPT pronounced symptoms mainly occurs in patients with chronic kidney disease (CKD), which is accompanied by pronounced osteoarticular syndrome, muscular weakness, neurological dysfunction, metastatic soft tissue calcification and calciphylaxis.

Calciphylaxis is a rare but very life-threatening complication of SHPT characterized by systemic calcification of arterioles, causing ischemia and subcutaneous necrosis [5]. This leads to an increased risk of cardiovascular disease and mortality. The mortality rate in these patients is by 6 to 7.8 times higher than in the general population [2, 6]. Until a certain moment, conservative treatment can slow down the course of the disease. Nevertheless, when drug therapy is not effective, the patient needs surgery [3]. According to international recommendations, subtotal parathyroidectomy should be performed in patients with CKD and disorders of bone mineral metabolism with drug treatment failure [8].

When surgery is postponed, changes occur in the structure of calcium and vitamin D receptors, contributing to the development of nodular hyperplasia and intraglandular adenomatous changes, the formation of an autonomous parathyroid parenchyma, which is unresponsive to drug correction [4]. Since drug resistance is due to the presence of nodular hyperplasia, subtotal parathyroidectomy remains the only effective method of treating SHPT and eliminating the symptoms of impaired calcium-phosphorus balance [1, 10].

The purpose of the study was to compare the results of surgical and conservative treatment of patients with secondary hyperparathyroidism with calcification and calciphylaxis.

Materials and methods. The study was carried out by comparing laboratory and instrumental diagnostic criteria in 31 patients who were operated on for SHPT or tertiary hyperparathyroidism (THPT), and in 32 patients who received conservative treatment. X-ray examination of the skeletal bones was carried out using the PHILIPS Diagnost – 76 Plus equipment (Netherlands).

Computer tomography of the mediastinum and bones was performed using the 'SIEMENS Somatom CR' apparatus (Germany). The extent of osteoporosis was determined according to a standardized technique with 'Achilles +' ultrasonic bone densitometer, manufactured by Lunar (USA) by measuring the integrated index of the calcaneal bone consistency, which shows both density and elasticity, as well as structural changes in the bone trabecular structure. This index is compared to the reference values for the respective populations and age norms. Radioisotopic scintigraphy of the parathyroid gland with ⁹⁹Tc-MIBI was performed using a single-photon emission tomograph "E. SRM" (Germany) and "OFEKT-1" (Ukraine).

X-ray examination, based on which the treatment efficacy, the therapy effect on the course and severity of osteodystrophy was assessed, was carried out at the beginning of treatment, after 3, 6 and 12 months.

Physical assessing symptoms include the general somatic state of the patient, the patient's weight (1 day after dialysis), blood pressure, pulse, the presence of skin scratches, general condition of the locomotion system, the hand muscles' strength, the dynamics of changes in subcutaneous calcifications (if any).

Among laboratory parameters, the level of PTH Ca, P, the level of hemoglobin and the number of erythrocytes, the concentration of total blood plasma protein were studied.

Clinical and laboratory data and patients' treatment results were processed and calculated according to parametric and nonparametric statistical methods using the integrated package for statistical analysis "Excel" MS Office 2010. The arithmetic mean and standard deviation were calculated and determined. Comparison of mean group values and assessment of the reliability of the difference was studied according to parametric and nonparametric methods of variation and rank statistics using the Student-Fisher t-test, Wilcoxon U-test, Mann-Whitney test.

Parametric methods were used to calculate the data of clinical trials and the results of patients' treatment in the case of numerous homogeneous observations (up to 30), which fit the Gaussian law of normal distribution. The Student's criterion was applied with a uniform distribution of the variation series, Fisher's criterion – with an uneven one. Methods of nonparametric rank statistics were used to calculate a small number of observations (up to 30), which were not subject to the law of normal distribution. The Wilcoxon-Mann-Whitney U-test was used due to its being the most stringent among all nonparametric tests and its being an analogue of the t-test for checking mean values.

Results of the study and their discussion. The most indicant symptoms in patients with SHPT or THPT were clinical manifestations of progressive osteodystrophy, which differed depending on the severity group of patients. The most informative was a pain in bones of certain localization (long bones of the upper and lower extremities, lumbar spine, ribs), as well as joint pain. In the group of patients where there was no increase in the level of PTH, it was observed in 5–11 %, with mild SHPT – in 2–20 %, in the group of severe hyperparathyroidism, these signs accompanied almost every patient (82–97 %). Progression of dystrophic and osteoporotic changes in bones, in addition to pain, led to severe disabling complications, such as limitation of joint mobility (in 7–71 %) and fractures (spontaneous or post-traumatic), which were observed in 7–55 %, depending on the severity of SHPT. Moreover, a distinctive manifestation of parathyroid osteodystrophy is a specific change in the patient's gait like a "duck" due to arthrosis of the hip joints and pain in the joints, which limits the range of motion. This manifestation was typical in half of the patients with moderate SHPT and in 79 % of severe SHPT cases.

In addition to pain in bones and joints, bone resorption results in restriction of movement in certain joints, skeletal deformities and neurological disorders when the spinal roots are compressed. The formation of "brown tumors", which are actually the result of granulomatous tissue development in the cancellous

bones at the site of pronounced fibroosteoclasia, also leads to compression of adjacent organs. In the studied patients, these formations were most often found in the mandible (fig. 1). When localized in the extremity area, such metastatic calcifications can cause significant impairment of motor function and joint mobility due to gross deformity of the extremity's anatomy (fig. 2).

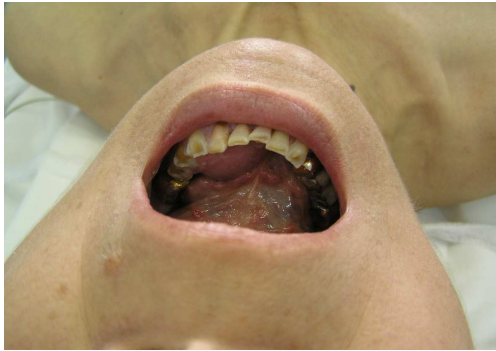

Fig. 1. The external view of the "brown tumor" in the mandible from the side of oral mucosa.

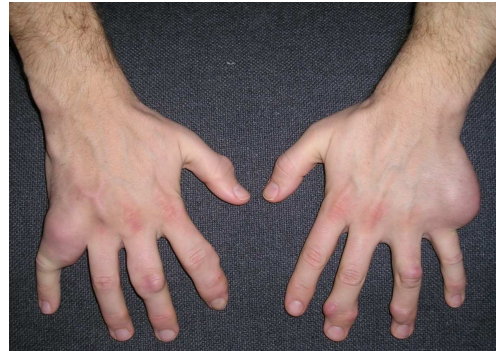


Fig. 2. Gross deformation of hands due to metastatic calcification of soft tissues.

Methods of instrumental diagnostics were used to both confirm the presence of SHPT and assess its severity and visualize the parathyroid glands properly.

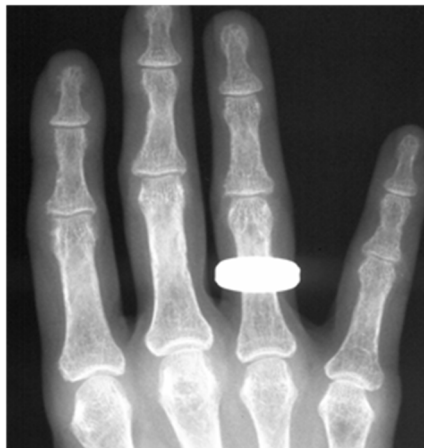

Fig. 3. Subperiosteal resorption of the hand phalanges in SHPT.

Since the main endpoint of PTH action is on the bone tissue, and the most important manifestations of SHPT are bone changes, the most adequate and accessible diagnostic method is radiography.

The earliest and most common example of bone tissue resorption is subperiosteal bone resorption. First, the proximal and middle phalanges of the hand fingers, especially their radial surfaces, underwent pathological changes. The jaggedness of the phalanges' contour and diffuse clearing of the cancellous bone structure were observed in almost all patients with CKD (fig. 3).

The prevalence of individual radiological symptoms in patients with SHPT is shown in table 1. As it can be seen from the results, the prevalence of radiological symptoms and, accordingly, the severity of osteodystrophy, increases with the severity of hyperparathyroidism.

After history of patients with SHPT were compared using the most pathognomonic and important symptoms, data of physical and laboratory-instrumental studies. Complaints and subjective symptoms of patients take place: general weakness, bone and joint pain, skin itching, limitation of motion, muscle cramps, depression, cardialgia.

□bl□1

Frequency of individual radiological symptoms in patients with SHPT, %

Radiological symptom	SHPT groups			Mean (n=134)
	Mild (n=62)	Moderate (n=34)	Severe (n=38)	
Subperiosteal bone resorption	81 % (51)	97 % (33)	100 % (38)	91 % (122)
Intracortical bone resorption	66 % (41)	79 % (27)	89 % (34)	76 % (102)
Erosive arthropathy	24 % (39)	65 % (22)	76 % (29)	67 % (90)
Bone deformation	8 % (5)	47 % (16)	55 % (21)	31 % (42)
Cystic osteodystrophy	3 % (2)	15 % (5)	58 % (22)	22 % (29)
"Brown" tumors	0	6 % (2)	16 % (6)	6 % (8)
Pathological fractures	6 % (4)	15 % (5)	55 % (21)	22 % (34)
Calcification of soft tissues	5 % (3)	12 % (4)	55 % (21)	21 % (28)

During the study, a group of patients with conservative treatment maintained their complaints or reported an increase in pain intensity. In contrast, the majority of subjective symptoms in patients after subtotal parathyroidectomy had a pronounced tendency to decrease. The most indicative is the fact that already in a few days after the surgery, there is an amelioration of signs in patients, skin itching (86 %) and bone pain (61 %) decrease. After 6 months, motion activity improved significantly (58–68 %).

Typical for this group of patients was an initial increase in the muscle cramps frequency (in 26 % after 1 month), followed by a gradual decrease in this symptom after 6 and 12 months in 27 % and 53 % of patients, respectively.

Prevalence of skin scratches detection was consistent with the subjective assessment of itching reduction after surgery and was observed in 16 % after 1 month and only in 3 % after 12 months. Trophic ulcers were only identified in 1 patient; they healed quickly within the first month after surgery.

Subcutaneous calcifications were detected by palpation in 6 patients of group 1 and in 3 patients of group 2. While in group 2 there was no positive dynamics (in 2 patients the calcification progressed), in group 1 after the surgery, the calcifications began to decrease after 3 months, and after 1 year they practically disappeared.

Summing up the dynamics of the indices shown in table 2, it is possible to clearly determine the general trend towards positive changes in patients who underwent surgery, in contrast to the group of patients with conservative treatment. At the same time, among laboratory parameters, the concentration of PTH decreased to normal values within a few days, the level of Ca × P – to a safe level.

Table 2

Dynamics of laboratory and instrumental-diagnostic parameters in the surgical (I) and therapeutic (II) groups of patients

Laboratory and instrumental parameters	Groups	Duration of observation (months)			
		Before surgery	1	6	12
Blood PTH (pg/ml)	I (31)	688±27	18±7*	34±12*	51±9*
	II (32)	612±24	634±25	665±27	681±27
Blood Ca _{total} (mmol/l)	I (31)	2.21±0.13	1.89±0.11	1.96±0.12	2.01±0.08
	II (32)	2.07±0.12	2.11±0.13	2.29±0.11	2.21±0.15
Blood P (mmol/l)	I (31)	2.07±0.11	1.97±0.12	1.81±0.11	1.83±0.14
	II (32)	1.98±0.14	1.93±0.13	2.08±0.16	2.09±0.15
Blood Ca×P (mmol/l) ²	I (31)	4.49±0.17	3.47±0.13*	3.65±0.16*	3.81±0.15*
	II (32)	4.29±0.14	4.31±0.17	4.56±0.18	4.48±0.17
Blood alkaline phosphatase (mU/l)	I (31)	492±39	431±30	320±22*	192±15*
	II (32)	357±27	389±32	396±27	382±24
Hemoglobin (g/l)	I (31)	97±11	99±8	107±12	119±12*
	II (32)	94±10	92±10	93±11	90±7
Blood serum protein (g/l)	I (31)	53±4	57±4	63±5	67±6
	II (32)	56±6	57±8	52±4	54±6
Osteodensitometry: density (% of the age norm)	I (31)	59±3	57±3	68±3	88±3*
	II (32)	63±3	64±3	61±3	60±3
Radiological signs of osteo-dystrophy regression (% of patients)	I (31)	0	10	16	52*
	II (32)	0	13	9	6
X-ray dynamics of fracture consolidation (% of patients)	I (12)	0	33	67	83*
	II (10)	0	10	30	40
X-ray dynamics of calcifications dissolution (% of patients)	I (9)	0	0	44*	89*
	II (6)	0	0	0	0
X-ray dynamics of vascular decalcification (% of patients)	I (6)	0	0	17	67*
	II (5)	0	0	0	0

* – the difference between the groups is significant (p<0.05).

SHPT occurs in patients with CKD and is associated with impaired calcium-phosphorus metabolism, parathyroid hyperplasia, and uncontrolled PTH secretion. PTH plays a key role in maintaining calcium and phosphorus levels in the body. In contrast to the primary hyperparathyroidism, in which there is an independent increased PTH secretion by the parathyroid gland's parenchyma, SHPT develops as a compensatory secretion of PTH due to hypocalcemia. Moreover, in patients with SHPT, the calcium level can either be elevated or remain within the reference values. In our study, patients with SHPT showed a decrease in calcium levels after subtotal parathyroidectomy with subsequent normalization of its level 12 months after surgery.

Metastatic calcification of soft tissues and calciphylaxis are common complications in patients with CKD, which are caused by impaired calcium-phosphorus balance and hyperparathyroidism [7]. Over the last years, there were a small number of publications in international literature sources concerning patients with calcification of various etiologies and manifestations, including SHPT [13, 14]. In our study, not only laboratory parameters of impaired phosphorus-calcium metabolism are presented as indications for surgical treatment, but also clinical manifestations of soft tissues' metastatic calcification.

According to the latest data, vascular calcification in SHPT is potentiated by an increased level of alkaline phosphatase in the blood. And this hypothesis is confirmed by a decrease in its level in the

postoperative period and, accordingly, by less pronounced clinical symptoms of calciphylaxis [11, 12], which is also observed in our study. Uremic arteriopathy is associated with skin necrosis and chronic ulceration, which leads to even more rapid mortality in patients with CKD [4, 6].

To date, various surgery procedures are presented to remove the destructive impact of PTH. The most preferred among surgeons is subtotal or total parathyroidectomy [1, 9, 15].

Subtotal parathyroidectomy remains the most effective and valid method for the treatment and amelioration of parathyroid nodular hyperplasia [10]. With this technique, identification and removal of three PTGs and subtotal resection of the fourth one, visually least altered PTG, are performed. This leaves 40 - 70 mg of the parenchyma in the fourth parathyroid gland. A distinctive advantage of this method is the moderate risk of transient postoperative hypocalcemia, which is amenable to conservative treatment and control [4].

Conclusion

Surgical treatment of SHPT and THPT is the most effective and safest method for patients with CKD. Surgical intervention quickly normalizes laboratory parameters in 96 % and eliminates clinical manifestations in 74–95 % of patients, reducing manifestations of soft tissue metastatic calcification and intravascular deposition of calcium crystals.

References

1. Tkachenko RP, Kurik OG, Golovko AS. Khirurgichne likuvannya vtorynnoho giperparatyreozu u patsientiv z khronichnoy khvoroboyu nyrok. *Klinichna khirurgiya*. 2018; 85(5), 47–50. <https://doi.org/10.26779/2522-1396.2018.05.47> [in Ukrainian]
2. Abdalla AO, Al-Khafaji J, Taha M, Malik S. A Fatal Case of Non-Uremic Calciphylaxis: A Case Report and Literature Review. *Am J Case Rep*. 2018 Jul 9; 19:804–807. doi: 10.12659/AJCR.909546.
3. Chiriac A, Grosu OM, Terinte C, Perța M. Calcific uremic arteriopathy (calciphylaxis) calls into question the validity of guidelines of diagnosis and treatment. *J Dermatolog Treat*. 2020 Aug; 31(5):545–548. doi: 10.1080/09546634.2019.1618435. Epub 2019 May 31. PMID: 31075991
4. Cocchiara G, Fazzotta S, Palumbo VD, Damiano G, Cajozzo M, Maione C. et al. The medical and surgical treatment in secondary and tertiary hyperparathyroidism. *Review Clin Ter*. 2017 Mar-Apr; 168(2):e158-e167. doi: 10.7417/CT.2017.1999.
5. Ellis CL, O'Neill WC. Questionable specificity of histologic findings in calcific uremic arteriopathy. *Kidney Int*. 2018 Aug; 94(2):390–395. doi: 10.1016/j.kint.2018.03.016. Epub 2018 Jun 7. PMID: 29885932.
6. Gaisne R, Péré M, Menoyo V, Hourmant M, Larmet-Burgeot D. Calciphylaxis epidemiology, risk factors, treatment and survival among French chronic kidney disease patients: a case-control study. *BMC Nephrol*. 2020 Feb 26; 21(1):63. doi: 10.1186/s12882-020-01722-y. PMID: 32101140.
7. Jankowski J, Floege J, Fliser D, Böhm M, Marx N. Cardiovascular Disease in Chronic Kidney Disease: Pathophysiological Insights and Therapeutic Options. *Circulation*. 2021 Mar 16; 143(11):1157–1172. doi: 10.1161/CIRCULATIONAHA.120.050686. Epub 2021 Mar 15. PMID: 33720773
8. Kim JS, Hwang HS. Vascular Calcification in Chronic Kidney Disease: Distinct Features of Pathogenesis and Clinical Implication. *Korean Circ J*. 2021 Dec; 51(12):961–982. doi: 10.4070/kcj.2021.0995. PMID: 34854578
9. Kim MS, Kim GH, Lee CH, Park JS, Lee JY, Tae K. Surgical Outcomes of Subtotal Parathyroidectomy for Renal Hyperparathyroidism. *Clinical and Experimental Otorhinolaryngology*. 2020 Feb 21; 13(2): 173–178. doi: 10.21053/ceo.2019.01340. PMID: 3207536.
10. Konturek A, Barczynski M, Stopa M, Nowak W. Subtotal parathyroidectomy for secondary renal hyperparathyroidism: a 20-year surgical outcome study. *Langenbecks Arch Surg*. 2016 Nov; 401(7):965–74. doi: 10.1007/s00423-016-1447-7. PMID: 27233241
11. Lau WL, Obi Y, Kalantar-Zadeh K. Parathyroidectomy in the management of secondary hyperparathyroidism. *Clin J Am Soc Nephrol*. 2018 Jun; 13(6):952–61. PMID: 29523679 PMID: PMC5989682 DOI: 10.2215/CJN.10390917.
12. Nigwekar SU, Sprague SM. We Do Too Many Parathyroidectomies for Calciphylaxis. *Semin Dial*. 2016 Jul; 29(4):312–4. PMID: 27082830 DOI: 10.1111/sdi.12502
13. Ruderman I, Hewitson TD, Smith ER, Holt SG, Wigg B, Toussaint ND. Vascular calcification in skin and subcutaneous tissue in patients with chronic and end-stage kidney disease. *BMC Nephrol*. 2020 Jul 16; 21(1):279. doi: 10.1186/s12882-020-01928-0. PMID: 32677907.
14. Starchenko II, Grinko RM, Shkodina AD, Filenko BM, Vynnyk NI, Roiko NV, et al. The Degree of Pineal Gland Calcification in the Aged People is Associated with Changes in the Internal Structure. *Journal of International Dental and Medical Research*. 2021; 14(2):841–44. <http://www.jidmr.com>
15. Won HR, Koo BS. Recent Trends in the Surgical Treatment of Secondary Hyperparathyroidism. *Clinical and Experimental Otorhinolaryngology*. 2020 May 1; 13(2): 91–92. doi: 10.21053/ceo.2020.00493.

Стаття надійшла 10.02.2021 р.