

O.D. Danyliv, V.I. Shepitko, O.S. Yakushko, Ye.V. Stetsuk, N.V. Boruta
Poltava State Medical University, Poltava

CHANGES IN THE TRIGEMINAL GANGLION OF RATS WITH ACUTE CARRAGEENAN-INDUCED INFLAMMATION

e-mail: stetsuk78@gmail.com

The purpose of the study was to establish the response of the components of the trigeminal ganglion in rats to aseptic inflammation under experimental conditions. The study was performed on 40 mature white male rats. Trigeminal ganglion of rats was the object of the study. The animals were divided into two groups: the control group of animals (5), which were injected with isotonic NaCl solution and the group of experimental animals (35), which were simulated acute carrageenan-induced inflammation. The rats were sacrificed within days 3, 5, 7, 10, 14, 21, and 30 under thiopental anesthesia overdose. Histological examination showed that carrageenan-induced inflammation in the trigeminal ganglion of rats had a staged course. Reactive changes in the vessels of the hemomicrocirculatory bed were most pronounced on the 5th day of observation. After that, the blood flow gradually stabilised until its complete normalization on the 14th day. Signs of reactive changes in neurons in the form of gradual oedema of the cytoplasm and nucleus and perinuclear chromatolysis were already noticed in the early stages of the experiment. The nature of the changes intensified with the increase in the observation period. Some cells showed signs of degenerative-dystrophic processes. The proliferative activity of glial cells increased in response to changes in neurons. The signs of inflammation in the parenchyma reached their maximum manifestation on the 14th day with an incomplete regeneration process for up to the 30th day.

Key words: trigeminal ganglion, inflammation, carrageenan, rats.

О.Д. Данилів, В.І. Шепітько, О.С. Якушко, Є.В. Стецук, Н.В. Борута

ЗМІНИ ТРІЙНИЧНОГО ГАНГЛІЯ ЩУРІВ ПРИ ГОСТРОМУ КАРРАГІНЕНОВОМУ ЗАПАЛЕННІ

Метою роботи було вивчення реакції компонентів трійчастого вузла щурів на асептичне запалення в умовах експерименту. Дослідження було проведено на 40 статевозрілих білих щурах-самцях. Об'єктом дослідження був трійчастий ганглії щурів. Тварини були розділені на 2 групи: контрольна група тварин (5), яким вводили ізотонічний розчин NaCl та група експериментальних тварин (35), яким було змодельовано гостре карагененове запалення. Щури були виведені з експерименту на 3, 5, 7, 10, 14, 21, 30 добу шляхом передозування тіопенталового наркозу. Гістологічне дослідження препаратів показало, що карагенін-індуковане запалення в трійчастому ганглії щурів мало стадійний характер перебігу. Реактивні зміни в судинах гемомікроциркуляторного русла були найбільш виражені на 5 добу спостереження, після чого відбувалася поступова стабілізація кровотоку до його повної нормалізації на 14 добу. Ознаки реактивних змін у нейронах у вигляді поступового набухання цитоплазми та ядра перинуклеарного хроматолізу були помітні вже в ранні терміни експерименту. Зі збільшенням термінів спостереження посилювався характер змін. У частини клітин спостерігалися ознаки дегенеративно-дистрофічних процесів. У відповідь зміни нейронів збільшилася проліферативна активність клітин глії. Максимального прояву ознаки запалення в паренхімі досягли на 14-ту добу із незавершеним процесом регенерації до 30-ї доби.

Ключові слова: трійчастий ганглії, запалення, карагенін, щури.

The study is a fragment of the research project "Experimental morphological study of cryopreserved placenta transplants action diphereline, ethanol and 1 % methacrylic acid on the morphofunctional status in a number of internal organs", state registration No. 0119U102925.

One of the most pressing clinical neurology and neurosurgery problems is trigeminal neuralgia. The prevalence of trigeminal nerve injuries at the present stage continues to be high and amounts to 30–50 patients per 100,000 population [3]. It does not tend to decrease, determined by the high level of injuries in the maxillofacial area and the increasing frequency of infectious diseases and metabolic disorders in the body [4, 11, 13].

According to the modern classification of trigeminal nerve system diseases, one of the causes of the pathology is the injury of the inflammatory genesis. It is characterized by changes in the interstitium, myelin sheath and/or irritation in the zone of innervation of its branches [10]. At the same time, the top place is occupied by neurogenic complications that develop with odontogenic inflammatory diseases of the jaws (periodontitis, periostitis, osteomyelitis, odontogenic subcutaneous granuloma, sinusitis, etc.), as well as with non-odontogenic inflammatory diseases (sinusitis, arthritis of the temporomandibular joints, non-specific and specific non-odontogenic inflammatory diseases of the jaws, etc.). Damage to the branches of the trigeminal nerve is also possible as a result of traumatic injuries to the bones of the face and

perimaxillary soft tissues, with postoperative injuries of the peripheral branches of the trigeminal nerve, post-filling injuries of the nerves and with narrowing of the bony canals, where the peripheral branches of the trigeminal nerve pass [6, 7].

Thus, studying the characteristics of the reaction of the components of the nervous tissue to inflammatory processes to study further the possibility of correcting the course of pathological processes is an urgent task of modern morphological science.

The purpose of the study was to establish the response of the components of the trigeminal ganglion in rats to aseptic inflammation under experimental conditions.

Materials and methods. The study was performed on 40 white mature male rats. Animals were kept in the experimental biological clinic of the Poltava State Medical University according to standard sanitary regulations on a balanced diet. When working with animals, we were guided by the general ethical principles of working with experimental animals, “European Convention For the Protection of Vertebrate Animals Used for Experimental and Other Scientific Purposes”; (Strasbourg, 1986), as well as the “General Ethical Principles of Animal Experiments” adopted by the First National Congress on Bioethics (Kyiv, 2001).

Trigeminal ganglion of rats was the object of the study.

The animals were divided into two groups: the control group (5) and the experimental group of animals (35). The acute aseptic inflammation was administered by 5 mg of λ -carrageenan (Sigma, USA) intraperitoneal injection in 1 ml of isotonic NaCl solution per animal [15]. Rats from the control group received an injection of saline.

The rats were sacrificed within days 3, 5, 7, 10, 14, 21, and 30 under thiopental anesthesia overdose. The material for the study was fixed in a 10 % neutral formalin solution for three days. The material was embedded in paraffin blocks, of which sections 4 μ m thick were made using standard methods [1]. Histological preparations were stained with hematoxylin, eosin, and the Nissl method [11].

Histological preparations were examined using Biorex 3 light microscope with a digital microfilter with software adapted for these studies (serial No. 5604). Statistical processing of the study results was performed using Microsoft Office Excel software and the Real Statistics 2019 extension [9]. The difference was considered statistically significant at $p < 0.05$.

Results of the study and their discussion. A histological examination of the trigeminal ganglion of rats in the control group of animals showed that the stroma of the organ and the vessels of the hemomicrocirculatory bed were intact.

The neurons had a rounded nucleus located in the center, with a large, well-defined nucleolus. The chromatophilic substance was heterogeneous, in the form of clumps found perinuclearly, as well as in a dispersed form throughout the cytoplasm.

The bundles of nerve fibers fit snugly together.

According to morphometric data, the volume of the cell cytoplasm was $3489.89 \pm 129.53 \mu\text{m}^3$, the volume of the nucleus was $247.68 \pm 11.07 \mu\text{m}^3$. The number of satellite cells per neuron is, on average, 3.48 ± 0.16 . The volumetric density index of trigeminal ganglion neurons was $28.93 \pm 0.55 \%$.

The study of the trigeminal ganglion in rats of the experimental group on the 3rd day showed that the stroma of the organ was actively involved in the inflammatory process. This was manifested by edema of collagen fibers and the connective tissue intercellular substance. The vessels of the microcirculatory bed were dilated, and stasis was observed.

Among the population of neurons, there were intact cells with a centrally located rounded nucleus, in which 1–2 nucleoli were visible. The chromatophilic substance was presented in a dispersed form; it was evenly distributed throughout the cytoplasm. At the same time, cytoplasmic edema was observed in most neurons; the nucleus had uneven contours and an erased border. In most cells, the nucleus was shifted to the periphery. There were cells with pyknotic nuclei. Attention was drawn to the appearance of perineuronal voids (fig. 1).

The nerve fibers were closely adjacent to each other and viewed in equally directed bundles.

According to morphometric data, the cell volume was $6242.71 \pm 463.42 \mu\text{m}^3$, and the nucleus volume was $301.83 \pm 17.32 \mu\text{m}^3$.

The number of satellite glial cells per neuron averaged 3.77 ± 0.18 , which did not differ from that of the control group.

The volume density of neurons was $26.09 \pm 0.62 \%$, which is 10 % less than in the control group ($p < 0.01$) (table 1).

Table 1

Morphological parameters of trigeminal ganglion in acute aseptic inflammation

Parameters Days	Volume of the neurocyte cytoplasm, μm^3	Volume of neurocyte nucleus, μm^3	Number of satellite cells	Volumetric density index of neurons, %
Control group	3489.89 \pm 129.53	247.68 \pm 11.07	3.48 \pm 0.16	28.93 \pm 0.55
3	6242.71 \pm 463.42	301.83 \pm 17.32	3.77 \pm 0.18	26.09 \pm 0.62
5	6712.78 \pm 451.36	356.50 \pm 24.10	4.28 \pm 0.18	24.14 \pm 0.74
7	8581.77 \pm 522.59	387.37 \pm 15.83	4.37 \pm 0.13	23.61 \pm 1.32
10	8602.57 \pm 310.37	476.48 \pm 20.79	5.12 \pm 0.18	23.08 \pm 1.24
14	16211.78 \pm 803.99	576.53 \pm 27.97	5.64 \pm 0.22	21.54 \pm 1.48
21	8131.61 \pm 530.75	374.23 \pm 24.20	4.18 \pm 0.12	16.04 \pm 0.63
30	5760.72 \pm 421.44	327.75 \pm 12.37	3.72 \pm 0.17	14.32 \pm 0.83

The 5th day of the experiment was characterized by a further increase in changes in the vessels of the hemomicrocirculatory bed, which manifested by the phenomena of slow blood flow and stasis. Arterioles, capillaries and venules were dilated (fig. 2).

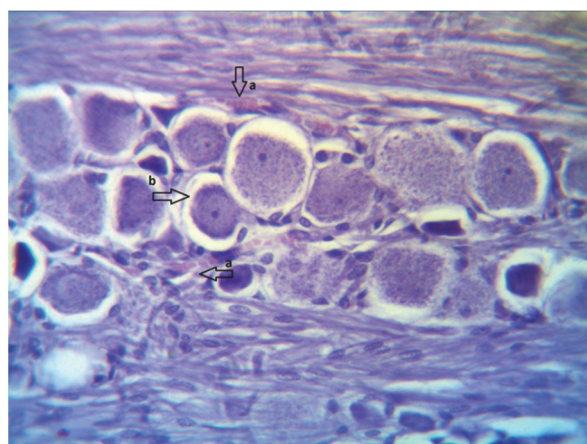


Fig. 1. Trigeminal ganglion of rats on the 3rd day of acute aseptic inflammation. Stasis in the vessels of the hemomicrocirculatory bed (a). The appearance of perineuronal voids (b). Hematoxylin-eosin staining. Lens: 40 \times magnification, ocular lens: 10 \times magnification.

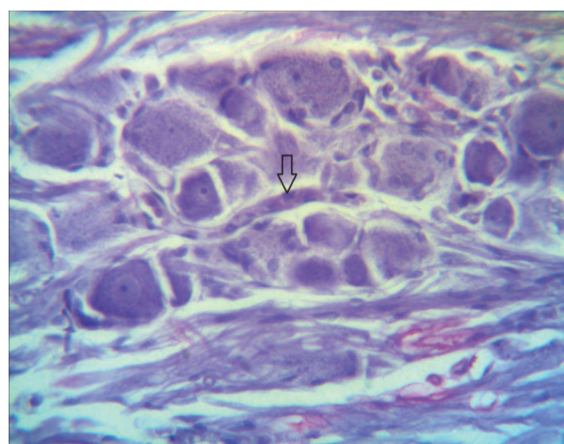


Fig. 2. Vessels of the hemomicrocirculatory bed of the trigeminal ganglion of rats on the 5th day of acute aseptic inflammation. H&E staining. Lens: 40 \times magnification, ocular lens: 10 \times magnification.

Connective tissue oedema increased compared to the previous observation period. The number of neurons with signs of reactive changes has increased. Cytoplasmic oedema was noticed in most neurons. The nuclei of neurons were swollen and ectopic.

There were cells of irregular shape with signs of perinuclear chromatolysis. In some neurons, the chromatophilic substance is visible in the form of clumps, evenly distributed throughout the cytoplasm. Edema persisted among the bundles of nerve fibers.

According to morphometric data, the cytoplasm volume of the cells was 6712.78 \pm 451.37 μm^3 , and the nuclei volume – was 356.50 \pm 24.10 μm^3 .

There was an increase in the number of glial cells surrounding neurons, especially those with chromatolysis phenomena. The average number of glial cells per neuron was 4.28 \pm 0.18, which was 1.23 times ($p < 0.01$) more than in the control group.

The value of the volumetric density of neurons decreased. It amounted to 24.14 \pm 0.74 %, which is 17 % less than the control group ($p < 0.01$).

When studying the structure of the trigeminal ganglion on the 7th day of the experiment, there was a tendency to normalize blood flow in the vessels of the hemocirculatory bed, with the resumption of the drainage function. This led to a decrease in connective tissue edema, both in the capsule and interstitium.

At the same time, most neurons showed cytoplasmic oedema, swelling of the nucleus with ectopia of the nucleolus, more pronounced than in the previous period. The chromatophilic substance is distributed differently in different cells. There were neurons with the phenomena of central chromatolysis. In some cells, the Nissl substance was located on the periphery in the form of clumps. The nucleus in such neurons was ectopic. The number of cells with pyknotic nuclei and phenomena of pericellular oedema increased.

Due to pronounced oedema, the nerve fibres had a tortuous pathway.

The volume of the cytoplasm of neurocytes increased by 2.5 times ($p<0.001$) compared with that in the control group and amounted to $8581.77\pm522.59 \mu\text{m}^3$. The nucleus volume became $387.37\pm15.83 \mu\text{m}^3$, which is 1.5 times ($p<0.001$) more than in the control group.

The average value of the number of satellite cells increased even more and amounted to 4.37 ± 0.13 per neuron, which is 1.26 times more ($p<0.01$) than in the control group.

There was a significant decrease in the volumetric density of neurons by $23.61\pm1.32 \%$, which is 19 % less than that in the control group ($p<0.01$).

It should be noted that the 10th day of the experimental study was characterized by a further increase in destructive and degenerative changes in the cells of the trigeminal ganglion.

Along with the normalization of blood flow in the vessels of the hemomicrocirculatory bed and a decrease in stromal oedema, an increase in reactive processes in the ganglion parenchyma was observed. There was a further increase in the volume of the cytoplasm of neurocytes, nucleus oedema and ectopia. Some cells show marginal chromatolysis. There are neurocytes with pronounced destructive changes in the form of total chromatolysis and blurred boundaries of the nucleoli and nucleus. Shrinkage of neurons and formation of perineuronal voids were revealed.

By the 10th day of the experiment, the cytoplasm volume in the experimental group was $8602.57\pm310.37 \mu\text{m}^3$, the volume of the nucleus was $476.48\pm20.79 \mu\text{m}^3$.

The numerical value of satellite cells increased by 1.4 times ($p<0.01$) compared with the control group and amounted to 5.12 ± 0.18 . Their number significantly predominated around cells with chromatolysis and pyknosis phenomena (fig. 3A).

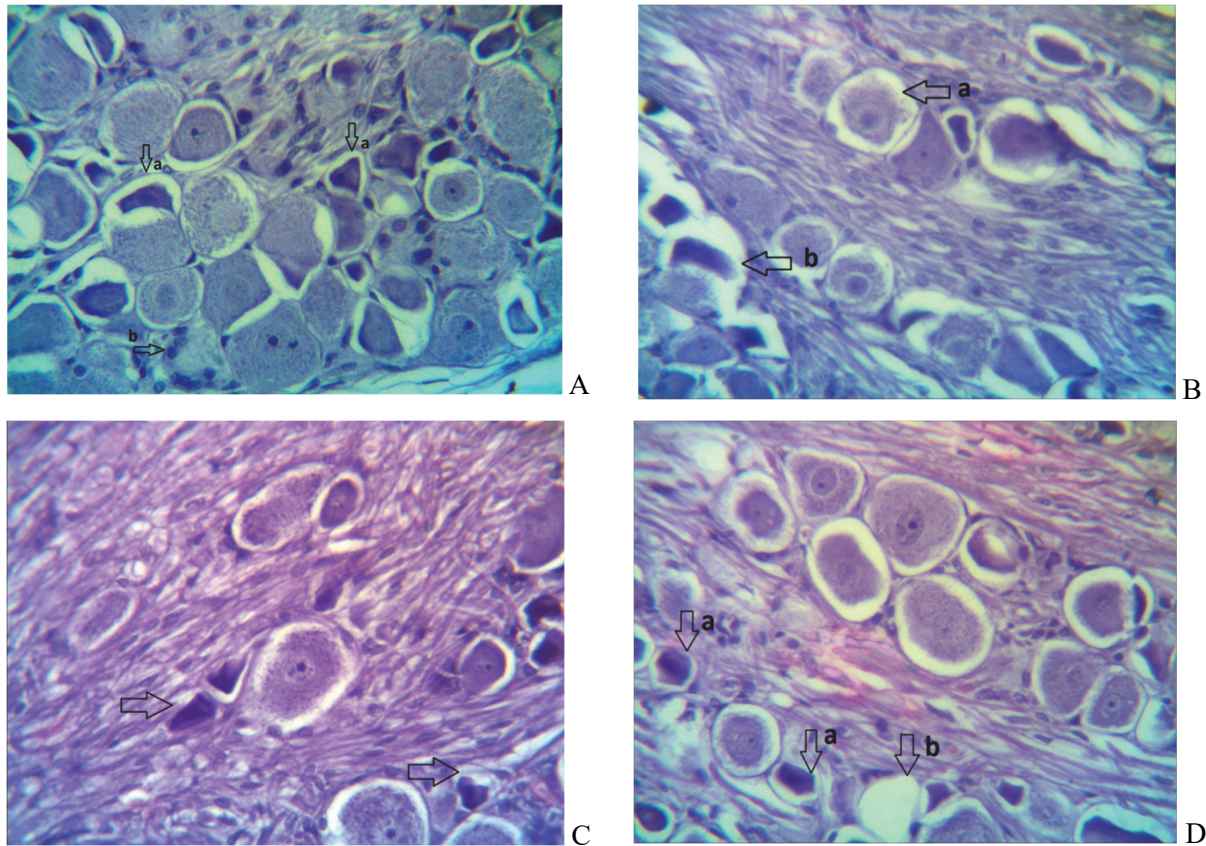


Fig. 3. Trigeminal ganglion of rats on acute aseptic inflammation. A – 10. B – 14. C – 2, D – 30 days. A: Pyknosis of neurocytes with the formation of perineuronal voids (a). B: Glial cells proliferation Neuron with a swollen cytoplasm and nucleus shifted to the periphery (a). Shrinkage of neurons (b). C and D: The neurons with a pyknotic nucleus, degenerative changes (a), and turning into “shadow cells” (b). Hematoxylin-eosin staining. Lens: 40×magnification, ocular lens: 10×magnification.

A further decrease in the volumetric density of neurons is noticeable at $23.08\pm1.24 \%$. This is 21 % less compared to the control group ($p<0.01$).

After 14 days of acute aseptic inflammation, there was a resumption of the morphofunctional activity of the vascular-stromal component of the trigeminal ganglion. At the same time, there was an increase in destructive processes in the parenchyma. The morphological picture was diverse. Attention is drawn to the polymorphism of neurons at the light microscopic level. Some cells had a swollen cytoplasm; a nucleus shifted to the periphery, and there was a pronounced phenomenon of central chromatolysis. Some of the cells underwent destructive changes. The cells were irregular in shape, with fuzzy, blurred contours.

The boundaries of the nuclei were poorly distinguishable. There was a noticeable shrinking of neurons with the formation of perineuronal voids (fig. 3B).

Bundles of nerve fibres were teased and had a tortuous pathway.

According to morphometric data, the most significant increase in the volume of the cytoplasm and the nucleus of neurons was observed. The volume of the cytoplasm was $16211.78 \pm 803.99 \mu\text{m}^3$; the nucleus was $576.53 \pm 27.97 \mu\text{m}^3$.

The number of satellite cells also increased in response to increased neurocytes with destructive changes. Their mean value was 5.64 ± 0.22 , 1.6 times more ($p < 0.01$) than in the control group and 1.3 times more ($p < 0.01$) than 7 days of the experiment.

The volumetric density of neurons was $21.54 \pm 1.48 \%$, which is 25 % less than the control group ($p < 0.01$).

On the 21st day of acute aseptic inflammation in the trigeminal ganglion, stabilization of blood flow in the vessels of the hemomicrocirculatory bed and the disappearance of oedema in the stroma were observed.

The neurocytes were heterogeneous in their structure. Some cells showed signs of regeneration, which consisted of a decrease in cytoplasmic oedema and restoration of the granular form of the chromatophilic substance. At the same time, neurons with characteristic signs of destructive changes in the form of chromatolysis, pyknosis of nuclei and cell shrinkage, with the formation of pericellular voids, were observed (fig. 3C).

Bundles of nerve fibres had a tortuous pathway.

According to morphometric data, the volume of the cytoplasm was $8131.61 \pm 530.75 \mu\text{m}^3$, the volume of the nucleus was $374.23 \pm 24.20 \mu\text{m}^3$. These parameters significantly differed from those in the control group but tended to decrease.

There was a decrease in the average value of the number of satellite cells. Their number was 4.18 ± 0.12 , which is 1.3 times less ($p < 0.01$) than the previous observation period. However, it was 1.2 times ($p < 0.01$) higher than the values in the control group.

Attention is drawn to a further decrease in the volumetric density of neurons to $16.04 \pm 0.63 \%$, which is 1.8 times less than in the control group and 1.3 times less than in the previous period.

After 30 days of acute aseptic inflammation, signs of regenerative processes were observed in the trigeminal ganglion of rats. The vessels of the hemomicrocirculatory bed and the ganglion stroma were intact. Most of the neurocytes had round or oval nuclei in the central part. The nucleoli in them are clearly defined. The chromatophilic substance was in the form of clumps or dispersed throughout the cytoplasm. However, there were neurons with a pyknotic nucleus, degenerative changes, irregular shape, intensely stained, wrinkling and lysis and turning into "shadow cells" (fig. 3D).

The nerve fibers were teased and twisted.

The volume of the cytoplasm of neurons was $5760.72 \pm 421.44 \mu\text{m}^3$, which is 1.4 times less ($p < 0.01$) than the previous period, but did not yet correspond to the parameters in the control group. The volume of the nucleus was $327.75 \pm 12.37 \mu\text{m}^3$.

The number of glial cells was 3.72 ± 0.17 , which did not significantly differ from the control group.

The volumetric density of neurons decreased by two times compared with the control group and amounted to $14.32 \pm 0.83 \%$.

Histological and morphometric studies of the trigeminal ganglion in rats with acute experimental inflammation confirm the stages of the process. The λ -carrageenan injected into the animal triggers a cascade mechanism of pathological reactions. On the 3rd day, they were manifested by impaired blood flow in the vessels of the hemomicrocirculatory bed, stasis. This, in turn, led to stromal oedema. These changes, characteristic of the exudative phase of inflammation, do not contradict the results obtained in other scientific papers [2, 8]. Reactive changes in the vessels of the hemomicrocirculatory bed were most pronounced on the 5th day of observation. After that, the blood flow gradually stabilised until its complete normalization on the 14th day. Following the stabilization of blood flow, a decrease in the stromal oedema of the trigeminal ganglion was observed.

The response of neurons to carrageenan-induced inflammation also showed characteristic variability [12, 14]. Signs of reactive changes in the form of gradual oedema of the cytoplasm and nucleus and perinuclear chromatolysis were already noticed in the early stages of the experiment. With an increase in the observation period, reactive changes in peripheral chromatolysis and nuclear ectopia also increased. Some cells pass into the stage of degenerative-dystrophic processes, which lead to irreversible changes and their death. Destructively altered neurons were wrinkled, irregularly shaped, with a pyknotic nucleus and a perineuronal space around the cells. The proliferative activity of glial cells increased in response to

changes in neurons. A gradual increase in reactive changes was observed on the 14th day of the experiment. Later, reparative processes were noted among neurons in the form of restoration of chromatophilic substance, centralization of the nucleus, and normalization of cytoplasm volume. However, degeneratively altered cells could not resume their functions. It should be noted that complete recovery of the parenchymal component did not occur on the 30th day. This was evidenced by an even increased parameter of the volume of the cytoplasm and nucleus and a reduced value of the volumetric density of neurons.

Conclusions

1. The λ -carrageenan injection caused acute aseptic inflammation of the trigeminal ganglion of rats, which had a staged course with pronounced manifestations, both in the stroma and in the parenchyma.

2. The most pronounced changes in the vascular-stromal component were observed on the 5th day of the study and were reversible. The parenchymal reaction manifested itself in varying degrees of neurocyte damage – from reactive processes to degenerative-dystrophic ones, with the active involvement of glial cells. The signs of inflammation in the parenchyma reached their maximum manifestation on the 14th day with an incomplete regeneration process up to 30 days.

References

1. Bahriy MM, Dibrova VA, Popadynets OH, Hryshchuk MI. Metodyky morfolohichnykh doslidzhen. Bahriy MM, Dibrova VA. redaktery. Vinnytsya: Nova knyha; 2016. 328s. [in Ukrainian]
2. Bista P, Imlach WL. Pathological Mechanisms and Therapeutic Targets for Trigeminal Neuropathic Pain. Medicines (Basel). 2019 Aug 22;6(3):91.
3. Cohen DT, Bragin I, Hwang R, Oselkin M. Cone Beam CT With Flat Panel Detector and Biplane Fluoroscopy-Guided Percutaneous Trigeminal Nerve
4. Daniliv OD, Stetsuk YeV, Boruta NV, Lukiantseva GV, Shepitko VI. Morphological features of the trigeminal ganglion in acute aseptic inflammation at the early stages of the experiment. World of Medicine and Biology. 2021;2(76):207–210.
5. De Santis D, Sinigaglia S, Faccioni P, Pancera P, Luciano U, Bertossi D, et.al. Syndromes associated with dental agenesis. Minerva Stomatol. 2019 Feb;68(1):42-56. doi: 10.23736/S0026–4970.18.04129-8.
6. Maarbjerg S, Di Stefano G, Bendtsen L, Cruccu G. Trigeminal neuralgia - diagnosis and treatment. Cephalalgia. 2017 Jun;37(7):648–657. doi: 10.1177/0333102416687280
7. Matsuda H, Sato I, Asaumi R, Omotehara T, Kawata S, Nagahori K, et.al. Comparison of CGRP distributions in the maxillary sinus and trigeminal ganglion between elderly dentulous and edentulous humans. Eur J Histochem. 2021 Mar 31;65(2):3234. doi: 10.4081/ejh.2021.3234.
8. Messlinger KJ. The big CGRP flood - sources, sinks and signalling sites in the trigeminovascular system. Headache Pain. 2018 Mar 12;19(1):22. doi: 10.1186/s10194-018-0848-0.
9. Rhizotomy Using Three-Dimensional Needle Trajectory Planning. Cureus. 2022 May 31;14(5): e25538.doi: 10.7759/cureus.25538.
10. Ritter A, Rozendorn N, Avishai G, Rosenfeld E, Koren I, Soudry E. Preoperative maxillary sinus imaging and the outcome of sinus floor augmentation and dental implants in asymptomatic patients. Ann Otol Rhinol Laryngol 2020; 129:209–15. DOI: 10.1177/0003489419883292
11. Shoji I, Kemuriyama T, Tandai-Hiruma M, Maruyama S, Tashiro A, Yokoe H, et.al. Reflex arc of the teeth clenching-induced pressor response in rats. J Physiol Sci. 2018 Jan;68(1):89–100. doi: 10.1007/s12576-016-0513-9.
12. Stelman CR, Buxton W, Sharon JD. Tapia's Syndrome (Concurrent Unilateral Recurrent Laryngeal and Hypoglossal Nerve Palsy) Following Left Retrosigmoid Craniotomy for Schwannoma Resection..Cureus. 2021 Sep 12;13(9): e17909. doi: 10.7759/cureus.17909.
13. Svyrydiuk RV, Shepitko KV, Shepitko VI, Raskaliei TY. Morphometric characteristics of the sciatic nerve trunk in the acute aseptic inflammation in rats. World of Medicine and Biology. 2018;2(64):173–75.
14. Yang Ni Y L, Han R, Guo G, Huang S, Weng L, Wang X, et.al. Implantable Peripheral Nerve Stimulation for Trigeminal Neuropathic Pain: A Systematic Review and Meta-Analysis. Neuromodulation. 2021 Aug;24(6):983–991. doi: 10.1111/ner.13421.
15. Zheng XB, Gao ZW, Mo HB, Lin Q, Wang HQ, Yu LH, et.al. Neuronavigation-assisted percutaneous radiofrequency thermocoagulation of trigeminal gasserian ganglion for refractory craniofacial pain.2018 Nov 20;98(43):3519–3523. doi: 10.3760/cma.j.issn.0376-2491.2018.43.011.

Стаття надійшла 23.11.2021 р.