

R.V. Martynenko, V.I. Shepitko, L.B. Pelypenko, N.V. Boruta, V.B. Martynenko,
O.V. Vilhova, Y.V. Stetsuk
Poltava State Medical University, Poltava

QUANTITATIVE AND QUALITATIVE CHANGES IN RED BONE MARROW MONOCYTE DIPHERONE AND MICROENVIRONMENTAL CELLS DURING LONG-TERM TRIPTORELIN ACETATE ADMINISTRATION IN THE EXPERIMENT

e-mail: mrv08102017@gmail.com

Prostate cancer is the most common cancer diagnosis among men, with more than 160,000 new cases each year in the United States. Huggins and Hodges demonstrated the therapeutic effect of testosterone deficiency in the gonads in the 1940s and thus confirmed the concept that prostate cancer is an androgen-dependent disease. Androgen deprivation therapy (ADT) is the main palliative treatment for men with locally advanced and metastatic prostate cancer, with the goal of reducing testosterone levels to the level obtained by surgical castration. The long-term chemical castration with triptorelin acetate leads to quantitative and qualitative changes in monocytic sprout cells at all levels of differentiation and proliferation with a complementary reaction of microenvironmental cells. The maximum quantitative changes in monocyte cells were observed at the 3rd month of the study, followed by a gradual recovery to the control group. Changes in the microenvironment cells: macrophages and reticular cells, were characterized by a stable reaction in the early stages of the study in the form of a decrease in the number and ratio of NSCs, with subsequent recovery of quantitative and qualitative changes to the level of the control group of animals. The adipocyte reacts at all stages of the study with a steady increase in quantitative and qualitative characteristics.

Key words: red bone marrow, monocytopenia, microenvironmental cells, triptorelin.

Р.В. Мартиненко, В.І. Шепітько, Л.Б. Пелипенко, Н.В. Борута, В.Б. Мартиненко,
О.В. Вільхова, Є.В. Стецук

КІЛЬКІСНІ ТА ЯКІСНІ ЗМІНИ МОНОЦИТАРНОГО ДИФЕРОНУ ЧЕРВОНОГО КІСТКОВОГО МОЗКУ ТА КЛІТИН МІКРООТОЧЕННЯ ПРИ ДОВГОТРИВАЛОМУ ВВЕДЕНІ ТРИПТОРЕЛІНУ АЦЕТАТУ В ЕКСПЕРИМЕНТІ

Рак передміхурової залози є найпоширенішим онкологічним діагнозом у чоловіків, більш ніж 160 000 нових випадків щороку в Сполучених татах. Хаггінс і Ходжес продемонстрували терапевтичний ефект дефіциту тестостерону в статевих залозах у 1940-х роках і таким чином підтвердили концепцію, що рак передміхурової залози є андрогензалежним захворюванням. Терапія депривації андрогенів (ADT) є основним паліативним методом лікування чоловіків з місцево-поширеним і метастатичним раком передміхурової залози, її метою є зниження рівня тестостерону до рівня, отриманого шляхом хірургічної кастрації. Довготривала хімічна кастрація триптореліном ацетатом призводить до кількісних та якісних змін клітин моноцитарного паростку на всіх стадіях диференціювання та проліферації з комплементарною реакцією клітин мікрооточення. Максимальні кількісні зміни клітин моноцитарного ряду спостерігалися на 3 місяці дослідження, з послідовним поступовим відновленням до показників контрольної групи. Зміни клітин мікрооточення: макрофагів та ретикулярних клітин, характеризувалася сталою реакцією на ранніх етапах дослідження у виді зменшення кількості та співвідношення ЯЦС, з послідовним відновленням кількісних та якісних змін до рівня контрольної групи тварин. Адипоцит реагує на всіх термінах дослідження сталим збільшенням кількісних та якісних характеристик.

Ключові слова: червоний кістковий мозок, моноцитопенія, клітини мікрооточення, трипторелін.

The study is a fragment of the research project "Experimental morphological study of cryopreserved placenta transplants action diphereline, ethanol and 1 % methacrylic acid on the morphofunctional status in a number of internal organs", state registration No. 0119U102925.

Prostate cancer is the most common cancer diagnosis among men, with more than 160,000 new cases each year in the United States. It is the second most common form of men's cancer, following only non-melanoma skin cancers [9]. Huggins and Hodges demonstrated the therapeutic effect of testosterone deficiency in the gonads in the 1940s and thus confirmed the concept that prostate cancer is an androgen-dependent disease [6]. Androgen deprivation therapy (ADT) is the main palliative treatment for men with locally advanced and metastatic prostate cancer, with the goal of reducing testosterone levels to the level obtained by surgical castration. Among the ADT options, the use of gonadotropin-releasing hormone (GnRH) agonists prevails. The GnRH agonist, triptorelin, is a first-line hormonal therapy that has demonstrated efficacy and safety in clinical trials of patients with locally advanced non-metastatic or metastatic disease [7, 11].

The effect of androgen deficiency on haematopoiesis is not sufficiently understood. Androgens have a dual effect on the hematopoietic system. As a result of the proliferation and differentiation of a polypotent blood stem cell under the influence of microenvironmental cells, all hematopoietic cells are developed [2]. In our opinion, the monocytopenia dipherone deserves special attention because of its active participation in the body's homeostasis. The effect of prolonged central deprivation of testosterone synthesis on quantitative and qualitative morphological changes in monocytopenia and its microenvironmental cells is not well understood and described in the scientific literature.

The purpose of the study was to determine the quantitative and qualitative changes in monocytopenia diphenylene and microenvironmental cells during chemical castration of male rats of central origin caused by the administration of triptorelin acetate solution during the year.

Materials and methods. The research was conducted on 30 adult male white rats. The rats were divided into 2 groups: Group I – control (5), which were injected with saline solution [3], animals of group II (25) were subcutaneously injected with triptorelin acetate in a dose of 0.3 mg of active ingredient per kg of body weight [5]. The animals were kept in standard conditions in the vivarium of Poltava State Medical University. The euthanasia of experimental animals was made in strict accordance with the provisions of the European Convention for the Protection of Vertebrate Animals Used for Experimental and Other Scientific Purposes (Strasbourg, 1986), as well as in accordance with the General Ethical Principles for Animal Experiments adopted by the First National Congress on Bioethics (Kyiv, 2001). Animals were euthanized according to the appropriate terms ($n=30$) by an overdose of ether anesthesia. Using standard methods, the material was compacted into paraffin blocks, and 4 μm thick sections were made and stained with hematoxylin and eosin [1]. The histological specimens were observed using a Biorex 3 light microscope with a digital microfilter with software adapted for these studies (serial number 5605) and digital camera M3CMOS 16000 16.OMP SIGETA (serial number 2005191327).

Statistical processing of the results was performed using Microsoft Office Excel and the extension Real Statistics 2019 to it. The nonparametric Mann-Whitney test was used to determine the statistical difference between the groups. The difference was considered statistically significant at $p<0.05$.

Results of the study and their discussion. During our study of semi-thin sections of rat red bone marrow at 1 month of the study, the structure of the bone marrow fully corresponded to the structure of the red bone marrow of intact rats, consisting of two main components: stromal and parenchymal. The stroma was represented mainly by reticular cells, which were interconnected by reticular fibers and formed a two-dimensional grid. The number of these cells in the intact group was 4.86 ± 0.147 (Table 1).

Table 1

Quantitative indices and nuclear-cytoplasmic ratio (NCR) of cells microenvironment of monocyte sprout of the study under chemical castration

	Macrophages of the red bone marrow	NCR	Adipocytes of the red bone marrow	NCR	Reticular cells of the red bone marrow	NCR
Control group	1.90 ± 0.076	0.183 ± 0.0166	4.69 ± 0.17	0.0503 ± 0.0086	4.86 ± 0.147	0.312 ± 0.0163
1 month	$1.74\pm 0.096^*$	$0.109\pm 0.0073^*$	4.43 ± 0.264	$0.0644\pm 0.0039^*$	4.24 ± 0.243	0.291 ± 0.017
3 months	$1.694\pm 0.093^*$	$0.111\pm 0.0073^*$	4.204 ± 0.255	$0.066\pm 0.0042^*$	4.041 ± 0.214	0.304 ± 0.01956
6 months	$1.877\pm 0.095^*$	$0.127\pm 0.00725^*$	$5.102\pm 0.262^*$	$0.0635\pm 0.00327^*$	$5.245\pm 0.285^*$	$0.2777\pm 0.015^*$
9 months	$1.898\pm 0.097^*$	$0.125\pm 0.00645^*$	$6\pm 0.255^*$	$0.0596\pm 0.00271^*$	4.489 ± 0.21	$0.411\pm 0.03^*$
12 months	$2.02\pm 0.111^*$	$0.127\pm 0.00567^*$	$7.224\pm 0.259^*$	$0.06\pm 0.00274^*$	5.224 ± 0.206	0.287 ± 0.015

Note: * – $p<0.05$, – the significant differences of the investigated indices compared to the analogous data in control rats.

During the first month of the study, we observed a slight statistically significant decrease in their number, with a decrease in the ratio of NSCs to cytoplasmic volume in the morphometric assessment of the area. In some places, a slight vacuolation of the cytoplasm was observed, the vacuoles were small in size and quantity, light. In the intervals between reticular cells there were cells of hematopoietic dipheron, between which there were cells of the microenvironment: macrophages of the red bone marrow, adipocytes.

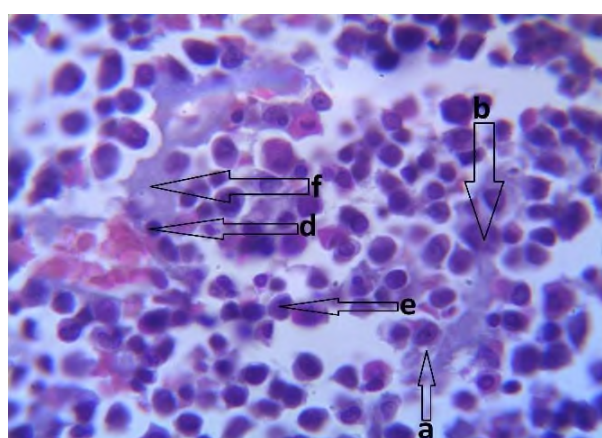
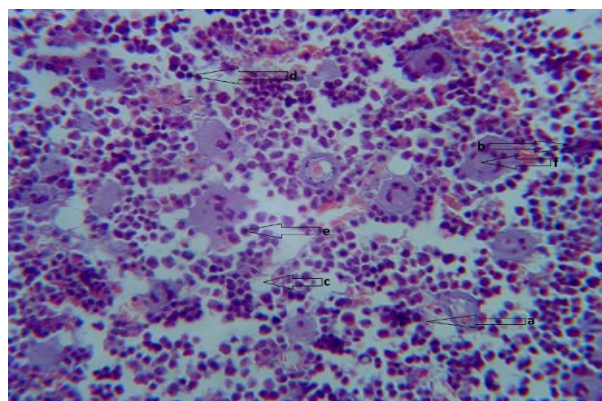
Red-bone macrophages were well visualized during morphological examination due to (description of macrophage). The number in the first month decreased compared to the intact group and amounted to 1.74 ± 0.096 . In the morphometric study of macrophages of the red bone marrow, a significant, statistically significant decrease in both the nucleus and cytoplasm area was determined compared to the intact group of animals (fig. 1).

Adipocytes are ellipsoidal cells, single, the number of which decreased in the first month of the study and amounted to 4.43 ± 0.264 , which is not statistically significant compared to the control group.

Studying the pool of differentiating cells of the monocyte lineage, we obtained a statistically significant decrease in the number of monoblasts and promonocytes, compared to the first month and the control group. And the number of monocytes increased and amounted to 6.02 ± 0.33 in the first month of observation, which is not a statistically significant increase compared to the control group (Table 2).

The third month of observation was characterized by an increase in blood filling of the organ, the vessels were enlarged in diameter, swollen, and the number of cells in their space was increased. The study of the microenvironment cells revealed a statistically significant decrease in these cells (adipocytes 4.204 ± 0.25 ; macrophages 1.694 ± 0.093 ; reticular cells 4.041 ± 0.214) compared to the control group and statistically unreliable compared to the previous follow-up period, due to swelling of the tissue itself and an increase in the number of capillaries per unit volume. The pericapillary space of the monocyte clone was mostly filled with cells at different stages of differentiation. There was a statistically significant

increase in the number of cells in the field of view (monoblasts 14 ± 0.427 ; promonocytes 13.551 ± 0.409 ; monocytes 12.959 ± 0.398) compared to both the control group and the first month of observation. Particular attention should be paid to mature forms (monocytes), which increased in number by more than 2 times compared to the previous observation period.



The sixth month of observation is characterized by a statistically significant increase in the number of cells of the microenvironment of the red bone marrow compared to the previous period (adipocytes 5.102 ± 0.262 ; macrophages 1.877 ± 0.095 ; reticular cells 5.245 ± 0.285); monocyte cells, in turn, statistically significantly decreased in number (monoblasts 12.734 ± 0.297 ; promonocytes 11.979 ± 0.274 ; monocytes 12.959 ± 0.204) compared to the previous period, but there is a statistically significant increase compared to the control group.

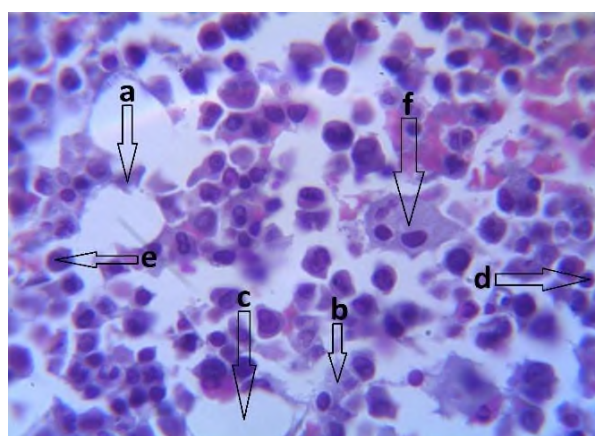


Fig. 1. Bone marrow. A – first month, B – third month, C – ninth month. (a) – reticular cells; (b) – macrophages; (c) – adipocytes; (d) – hematopoietic stem cells; (e) – monocytes; (f) – megakaryocyte. Hematoxylin-eosin staining. Lens: 40×magnification (A)/100×magnification (B, C), ocular lens: 10×magnification.

The ninth month of observation is characterized by a statistically significant decrease in the number of reticular cells 4.489 ± 0.21 , as well as a statistically significant increase in the number of cells of the microenvironment of the red bone marrow compared to the previous period (adipocytes 6 ± 0.255 ; macrophages 1.898 ± 0.097). The number of monocyte cells statistically significantly decreased (monoblasts 9.286 ± 0.302 ; promonocytes 8.531 ± 0.238 ; monocytes 7.286 ± 0.254) compared to the previous study period; also, a statistically significant decrease in progenitor cells is detected compared to the control group.

Table 2

Quantitative indices of monocytic sprout cells at different study periods in chemical castration

	Monoblasts	Promonocytes	Monocytes
Control group	5.65 ± 0.175	10.74 ± 0.184	5.65 ± 0.175
1 month	6.02 ± 0.33	8.92 ± 0.346	6.02 ± 0.33
3 months	$12.959 \pm 0.398^*$	$13.551 \pm 0.409^*$	$12.959 \pm 0.398^*$
6 months	$12.734 \pm 0.297^*$	$11.979 \pm 0.274^*$	$11.286 \pm 0.204^*$
9 months	$9.286 \pm 0.302^*$	$8.531 \pm 0.238^*$	$7.286 \pm 0.254^*$
12 months	$10.51 \pm 0.284^*$	9.816 ± 0.227	$8.469 \pm 0.254^*$

Note: * – $p < 0.05$, – the significant differences of the investigated indices compared to the analogous data in control rats.

At the twelfth month of observation, we have a statistically significant quantitative increase in all red bone marrow microcirculation cells (adipocytes 7.224 ± 0.259 ; macrophages 2.02 ± 0.111 ; reticular cells 5.224 ± 0.206) compared to the previous observation period and to the control group. Monocyte cells statistically significantly increased (monoblasts 10.51 ± 0.284 ; promonocytes 9.816 ± 0.227 ; monocytes 8.469 ± 0.254) compared to the previous study period. Compared to the control group, a statistically significant increase in the number of mature cells is noteworthy.

Our experimental study of red bone marrow during chemical castration affects the variability of the structural and functional parameters of its components. The obtained results coincide with the literature

data of other authors, in which the basic principles and regularities of the red bone marrow cell population and changes in them are outlined [10]. For men undergoing TTh, the risk of developing erythrocytosis compared with controls is well established, with short-acting injectable formulations having the highest associated incidence. Potential mechanisms explaining the relation between TTh and erythrocytosis include the role of hepcidin, iron sequestration and turnover, erythropoietin production, bone marrow stimulation, and genetic factors. High blood viscosity increases the risk for potential vascular complications involving the coronary, cerebrovascular, and peripheral vascular circulations, although there is limited evidence supporting a relation between TTh and vascular complications [4].

Androgens affect the erythropoiesis system, which leads to specific differences in the manifestations of many diseases depending on gender [15].

Testosterone propionate promoted the proliferation and maintained the viability of bone marrow-derived mesenchymal stem at 10⁻⁸ M concentration. Further evaluations were conducted with the determined dose. The results showed that, apart from promoting mesenchymal stem cells' polarization and increasing their cytotoxicity on K562 cells, testosterone propionate did not alter differentiation capacities of bone marrow-derived mesenchymal stem cells and certain cell surface markers, but led to a significant increase in HLA-DR expression. [12]. Androgens regulate the immune system, which causes specific differences in the manifestations of many diseases depending on gender [8,14].

The maximum quantitative changes in monocyte cells were observed at the 3rd month of the study, followed by a gradual recovery to the control group. Changes in the microenvironment cells: macrophages and reticular cells, were characterized by a stable reaction in the early stages of the study in the form of a decrease in the number and ratio of NSCs. In general, androgens have an anti-inflammatory effect, while estrogens cause pro-inflammatory effects. Androgens negatively affect inflammation (e.g., in asthma) by targeting innate lymphoid cells type 2 (ILC2) and T helper (Th)-2 cells to attenuate the interleukin (IL)-17A-mediated response through leukotriene (LT) biosynthesis [13].

Conclusion

The long-term chemical castration with triptorelin acetate leads to quantitative and qualitative changes in monocytic sprout cells at all levels of differentiation and proliferation with a complementary reaction of microenvironmental cells. The maximum quantitative changes in monocyte cells were observed at the 3rd month of the study, followed by a gradual recovery to the control group. Changes in the microenvironment cells: macrophages and reticular cells, were characterized by a stable reaction in the early stages of the study in the form of a decrease in the number and ratio of NSCs, with subsequent recovery of quantitative and qualitative changes to the level of the control group of animals. The adipocyte reacts at all stages of the study with a steady increase in quantitative and qualitative characteristics.

References

1. Bahriy MM, Dibrova VA, editors. *Metodyky morfolohichnykh doslidzhen*. Vinnytsya: Nova knyha; 2016. 328s. [in Ukrainian]
2. Martynenko RV. Vplyv tsentralnoyi deprivatsiyi testosteronu na strukturnu orhanizatsiyu monotsytarnoho klonu chervonoho kistkovoho mozku v ranni termyny eksperymentu. Aktualni problemy suchasnoyi medytsyny. 2021; 21, 2 (74). doi 10.31718/2077-1096.21.2.142. [in Ukrainian]
3. Albadrani GM, Binmowyna MN, Bin-Jumah MN, El-Akabawy G, Aldera H, Al-Farga AM. Quercetin protects against experimentally-induced myocardial infarction in rats by an antioxidant potential and concomitant activation of signal transducer and activator of transcription. *J Physiol Pharmacol*. 2020 Dec; 71(6): 125–7. doi: 10.26402/jpp.2020.
4. Başak Ar, Tuba A, Hüsnüye D, Gizem G, Gülderen YD. Testosterone propionate promotes proliferation and viability of bone marrow mesenchymal stem cells while preserving their characteristics and inducing their anti-cancer efficacy. *Balkan Med JFeb* 7. doi: 10.4274/balkanmedj.galenos.2022.2022-10-21.
5. Botté MC, Lerrant Y, Lozach A, Bérault A, Counis R, Kottler ML. LH down-regulates gonadotropin-releasing hormone (GnRH) receptor, but not GnRH, mRNA levels in the rat testis. *J Endocrinol*. 1999; 162(3): 40915. doi:10.1677/joe.0.1620409.
6. Desai K, McManus JM, Sharifi N. Hormonal Therapy for Prostate Cancer. *Endocrine Reviews*. Volume 42, Issue 3, June 2021, Pages 354–373. doi: 10.1210/endrev/bnab002.
7. Huang C, Pang H, Wang L, Niu Y, Luo J, Chang E, et al. New therapy via targeting androgen receptor in monocytes/macrophages to battle atherosclerosis. *Hypertension*. 2014 Jun;63(6):1345–53. doi: 10.1161/HYPERTENSIONAHA.113.02804.
8. Jorgensen TN, Kovats S, Lotter H. Effects of Androgens on Immunity to Self and Foreign. *Frontiers in Immunology*. 2020; 11:3476. doi: 10.3389/fimmu.2020.630066.
9. Litwin MS, Tan H. The Diagnosis and Treatment of Prostate Cancer: A Review. *JAMA*. 2017;317(24):2532–2542. doi:10.1001/jama.2017.7248.
10. Lucas D. Structural organization of the bone marrow and its role in hematopoiesis. *Current Opinion in Hematology* 28(1): 36–42, January 2021. doi: 10.1097/MOH.0000000000000621.
11. Merseburger, AS, Hupe MC. An Update on Triptorelin: Current Thinking on Androgen Deprivation Therapy for Prostate Cancer. *Adv Ther*. 2016; 33, 1072–1093. doi: 10.1007/s12325-016-0351-4.
12. Ohlander SJ, Varghese B, Pastuszak AW. Erythrocytosis following testosterone. *Therapy Sex Med Rev*. 2018 Jan;6(1):77–85. doi:10.1016/j.sxmr.2017.04.001.

13. Reyes-García J, Montaño LM, Carbajal-García A, Wang YX. Sex Hormones and Lung Inflammation. In: Wang, YX. (eds) Lung Inflammation in Health and Disease, Volume II. Advances in Experimental Medicine and Biology. 2021; 1304. Springer, Cham. doi: 10.1007/978-3-030-68748-9_15.
14. Rud MV, Shepitko VI, Stetsuk YeV, Akimov OYe, Vilkhova OV, Skotarenko TA. The reaction of immunocompetent liver cells during chemical castration of male rats caused by the introduction of triptorelin acetate. World of Medicine and Biology. 2021. № 2 (76): 238–242. doi: 10.26724/2079-8334-2021-2-76-238-242.
15. Woods GN, Ewing SK, Sigurdsson S, Kado DM. Greater bone marrow adiposity predicts bone loss in older women. J Bone Miner Res. 2020 Feb;35(2):326–332. doi: 10.1002/jbmr.3895.

Стаття надійшла 24.02.2022 р.

DOI 10.26724/2079-8334-2023-1-83-218-223

UDC 616-092.9+663.8+577.15

Kh.Yu. Partsei, H.M. Ersteniuk, S.V. Shkurashivska, I.P. Kindrat, V.M. Senchiy
Ivano-Frankivsk National Medical University, Ivano-Frankivsk

STATUS OF PRO- AND ANTIOXIDANT SYSTEM OF RATS UNDER CONDITIONS OF ENERGY DRINK CONSUMPTION

e-mail: hrustuna012y@gmail.com

The article is devoted to the study of the mechanism of the impact of energy drinks on the state of pro- and antioxidant system of erythrocytes of experimental animals. The study was carried out on male Wistar rats. We found that in the erythrocytes of experimental animals that consumed an energy drink for 30 days, the processes of free radical oxidation are activated, accompanied by the activation of lipo-peroxidation and peroxidation of proteins in experimental animals. Accumulation of the thiobarbituric acid active products and the content of diene conjugates can damage the lipid matrix of biomembranes, which in turn leads to disruption of the structural and functional capacity of erythrocyte cell membranes. High levels of protein carbonyl derivatives of erythrocytes may be due to disruption of both structural proteins and enzymes. Under such conditions, it is advisable to study the antioxidant defense of erythrocytes. The obtained results indicate an increase in catalase and superoxide dismutase activity in experimental animals compared with the control group, which may be due to the growth in the peripheral population of “early” forms of cells which are capable of active protein synthesis. This process can be considered as an adaptive synthesis of antioxidant enzymes. The study of the microelement status of rat erythrocytes under the conditions of energy consumption allowed to establish the development of dysmicroelementosis, which was accompanied by a decrease in the concentration of Copper and Ferrum.

Key words: laboratory rats, energy drink, catalase, superoxide dismutase, TBK-active products, diene conjugates oxidative modification of proteins.

Х.Ю. Парцей, Г.М. Ерстенюк, С.В. Шкурашівська, І.П. Кіндрат, В.М. Сенчій

СТАН ПРО- ТА АНТИОКСИДАНТНОЇ СИСТЕМИ ЩУРІВ ЗА УМОВ СПОЖИВАННЯ ЕНЕРГОНАПОЮ

Стаття присвячена вивченню механізму впливу енергетичного напою на стан про- та антиоксидантної системи еритроцитів експериментальних тварин. Дослідження було проведено на щурах-самцях лінії Вістар. Нами встановлено, що в еритроцитах експериментальних тварин, які споживали енергетичний напій протягом 30 днів, активуються процеси вільнорадикального окиснення, що супроводжуються активацією процесів ліпопероксидації та пероксидації білків. Накопичення ТБК-активних продуктів та дієнових кон'югатів може призвести до пошкодження ліпідного матриксу біомембран, що в свою чергу зумовлює порушення структурно-функціональної здатності клітинних мембран еритроцитів. Високий рівень карбонільних похідних білків еритроцитів може бути зумовлений порушенням як структурних білків, так і ензимів. За таких умов доцільним є дослідження антиоксидантного захисту еритроцитів. Отримані результати свідчать про збільшення активності каталази та супероксиддисмутази у дослідних тварин порівняно з контрольною групою, що може бути зумовлене зростанням у периферичній популяції «ранніх» форм клітин, які здатні до активного білкового синтезу. Такий процес можна розглядати як адаптивний синтез антиоксидантних ферментів. Дослідження мікроелементного статусу еритроцитів щурів за умов споживання енергетика дозволило встановити розвиток дисмікроелементозу, що супроводжувався зниженням концентрації Купруму та Феруму.

Ключові слова: лабораторні щурі, енергетичний напій, каталаза, супероксиддисмутаза, ТБК-активні продукти, дієнові кон'югати, окисна модифікація білків.

The study is a fragment of the research project “Scientific substantiation and improvement of diagnosis and treatment of endocrinopathies based on the study of priority epipathogenetic factors and comorbid conditions” state registration No. 0120U105103.

Consumption of energy drinks has increased worldwide since they appeared on the market in 1987 [13]. The purpose of drinking such drinks is to improve physical endurance, increase physiological and cognitive reactions, reduce sleep needs. The main ingredients of energy drinks are caffeine, taurine, guarana, carbohydrates, sodium and vitamin B₆. Some energy drink brands also include glucuronolactone, ginseng, ginkgo biloba [9]. Due to the presence of these components, energy drinks eliminate the signs of